



Diagnosis, Management, and Treatment of Female Genital Mutilation or Cutting in Girls

Janine Young, MD, FAAP;^a Nawal M. Nour, MD, MPH, FACOG;^b Robert C. Macauley, MD, FAAP;^c Sandeep K. Narang, MD, JD, FAAP;^d Crista Johnson-Agbakwu, MD, MSc, FACOG;^e SECTION ON GLOBAL HEALTH, COMMITTEE ON MEDICAL LIABILITY AND RISK MANAGEMENT, COMMITTEE ON BIOETHICS

Female genital mutilation or cutting (FGM/C) involves medically unnecessary cutting of parts or all of the external female genitalia. It is outlawed in the United States and much of the world but is still known to occur in more than 30 countries. FGM/C most often is performed on children, from infancy to adolescence, and has significant morbidity and mortality. In 2018, an estimated 200 million girls and women alive at that time had undergone FGM/C worldwide. Some estimate that more than 500 000 girls and women in the United States have had or are at risk for having FGM/C. However, pediatric prevalence of FGM/C is only estimated given that most pediatric cases remain undiagnosed both in countries of origin and in the Western world, including in the United States. It is a cultural practice not directly tied to any specific religion, ethnicity, or race and has occurred in the United States. Although it is mostly a pediatric practice, currently there is no standard FGM/C teaching required for health care providers who care for children, including pediatricians, family physicians, child abuse pediatricians, pediatric urologists, and pediatric urogynecologists. This clinical report is the first comprehensive summary of FGM/C in children and includes education regarding a standard-of-care approach for examination of external female genitalia at all health supervision examinations, diagnosis, complications, management, treatment, culturally sensitive discussion and counseling approaches, and legal and ethical considerations.

abstract

^aDepartment of General Pediatrics, Denver Health Refugee Clinic, and Human Rights Clinic, Denver Health and Hospitals and School of Medicine, University of Colorado Denver, Denver, Colorado; ^bAfrican Women's Health Center, Department of Obstetrics and Gynecology, Brigham and Women's Hospital and Harvard Medical School, Harvard University, Boston, Massachusetts; ^cDepartment of Pediatrics, Oregon Health and Science University, Portland, Oregon; ^dDivision of Child Abuse Pediatrics, Ann and Robert H. Lurie Children's Hospital of Chicago and Department of Pediatrics, Feinberg School of Medicine, Northwestern University, Chicago, Illinois; and ^eRefugee Women's Health Clinic, Department of Obstetrics and Gynecology, Valleywise Health Medical Center and Office of Refugee Health, Southwest Interdisciplinary Research Center, School of Social Work, Watts College of Public Service and Community Solutions, Arizona State University, Phoenix, Arizona

Clinical reports from the American Academy of Pediatrics benefit from expertise and resources of liaisons and internal (AAP) and external reviewers. However, clinical reports from the American Academy of Pediatrics may not reflect the views of the liaisons or the organizations or government agencies that they represent.

The guidance in this report does not indicate an exclusive course of treatment or serve as a standard of medical care. Variations, taking into account individual circumstances, may be appropriate.

All clinical reports from the American Academy of Pediatrics automatically expire 5 years after publication unless reaffirmed, revised, or retired at or before that time.

To cite: Young J, Nour NM, Macauley RC, et al. AAP SECTION ON GLOBAL HEALTH, AAP COMMITTEE ON MEDICAL LIABILITY AND RISK MANAGEMENT, AAP COMMITTEE ON BIOETHICS. Diagnosis, Management, and Treatment of Female Genital Mutilation or Cutting in Girls. *Pediatrics*. 2020;146(2):e20201012

BACKGROUND

Female genital mutilation or cutting (FGM/C)* is currently outlawed in much of the world. The United Nations,¹ the World Health Organization (WHO),² the International Federation of Obstetrics and Gynecology,³ and the American Medical Association⁴ are among multiple organizations that unequivocally oppose all forms of FGM/C (see Table 1).

FGM/C involves medically unnecessary cutting of parts or all of the external female genitalia, including the clitoris, prepuce, labia minora, and labia majora. FGM/C may be associated with significant morbidity and mortality and is not associated with any medical benefit. Notwithstanding this morbidity, it is still performed and has been practiced in many cultures for thousands of years, predating Judaism, Christianity, and Islam.⁵ Historically and in present-day, FGM/C is a cultural practice not directly tied to any specific religion, ethnicity, or race and has been reported to still occur throughout the world, including in the United States, but with higher prevalence in parts of the Middle East, Asia, and Africa (see Fig 1). Reasons why FGM/C is performed vary by region and culture and may include a belief that it increases marriageability, preserves virginity, improves hygiene, perpetuates

a traditional rite of passage, and/or upholds prescribed religious beliefs (although no sacred texts recommend this practice).^{6,7} FGM/C is predominantly performed on children and adolescents ranging in age from newborn infants to 15 years; the typical age varies by region of the world, country, state, province, and even town or village⁸ (see Fig 2). However, the vast majority of medical literature, teaching, and research is focused on chronic issues affecting women of childbearing age and on the management of FGM/C during pregnancy and the peripartum and postpartum periods.^{9,10}

To date, there are neither national nor international clinical practice guidelines that are specifically focused on FGM/C in infants and prepubertal and pubertal girls.

This clinical report's primary goal is to educate pediatric health care providers on the continued occurrence of FGM/C, the populations that it affects, diagnosis, complications, treatment options, and the provision of culturally sensitive counseling, all while taking into consideration the legal and ethical aspects of a practice that is illegal in the United States and much of the world (see Table 2).

PREVALENCE

National and international data on the prevalence of FGM/C in children and adolescents are difficult to obtain and are based on either maternal report or estimates derived from data on the adult female population who present mainly for obstetrical care. The United Nations Children's Fund estimated that in 2018, 200 million girls and women alive at that time had undergone FGM/C worldwide.¹¹ Some authors estimate that more than 500 000 girls and women who live in the United States (as of 2012) have had FGM/C performed or are at

risk for having FGM/C performed, but these estimates are projections based on country of origin prevalence data and may, therefore, not be precise or accurate.¹³ To date, no reliable data exist quantifying the true number of girls and women residing in the United States who have had FGM/C performed.¹³

The majority of FGM/C occurs in 30 African and Middle Eastern countries, with highest prevalence in Egypt, Somalia, Guinea, Djibouti, Mali, Sierra Leone, Sudan, and Eritrea.¹⁴ However, FGM/C also occurs with unknown frequency in Yemen, Oman, the United Arab Emirates, Bahrain, northern Iraq, India, Malaysia, and Indonesia¹⁵ and has been reported to occur sporadically in Russia^{16,17} and Colombia.¹⁸ The practice of FGM/C is not uniformly performed throughout any given country and may be clustered on the basis of economic status, level of education, rural versus urban geographic location, ethnic and/or tribal affiliation, and religious beliefs. In half of the countries with available data on FGM/C prevalence, most girls have had FGM/C performed before 5 years of age (see Fig 2).

Although it is illegal in the United States, FGM/C has been reported in the United States in sporadic cases over the past several years.^{19,20} The federal Department of Justice prosecuted its first case against a US physician accused of having performed FGM/C across state lines in up to 100 children (see The Law and FGM/C in Minors in the United States for further current case details).²¹ At time of writing, the charges were dismissed by the district judge of the Eastern District of Michigan.²² This specific case is focused on the practice of FGM/C in the Dawoodi Bohra community in India and among a subset of the Dawoodi Bohra immigrant community in the United States. The illegal practice of US families sending their children abroad to have FGM/C

* Currently, there are few experts in the United States who care for children and teenagers with FGM/C (see Table 4 for a link to access regional specialists). As such, it is of utmost importance to identify regional specialists, including child abuse pediatricians, gynecologists, urologists, and mental health providers, with whom to collaborate if providing medical care for children and teenagers affected by or at risk for FGM/C. FGM/C is an accepted term adopted by many international organizations and in medical research papers and, as such, will be used throughout this document.^{9,12,16} Infibulation refers to type III FGM/C (see FGM/C Types and Classification in addition to Fig 4). Defibulation refers to a surgical procedure that opens the scar formed in patients with type III FGM/C (see Defibulation).

TABLE 1 FGM/C Recommendations

Recommendations
FGM/C is illegal in the United States.
FGM/C is a violation of human rights.
FGM/C has no medical benefit.
FGM/C is associated with serious and potentially life-threatening complications that can have lifelong impacts on health.
Health care providers should not perform any type of FGM/C on female infants, girls, or teenagers.
Health care providers caring for girls at risk for FGM/C should actively counsel families against performing FGM/C, including when families travel to countries where FGM/C is practiced.
A genital examination allows health care professionals to identify FGM/C and other medical findings of significance.
If genital examination findings are equivocal for the presence of FGM/C and risk factors for FGM/C are present, a specialist trained in identification of FGM/C should be consulted (see Table 4).
The management of FGM/C should include complete documentation of clinical findings and the use of ICD-10 coding.
Health care providers should recommend defibulation for all girls and teenagers with type III FGM/C, irrespective of whether complications are currently present.

performed (also known as “vacation cutting”) is also presumed to occur.^{23,24} However, prevalence data are nonexistent to date.¹³

FGM/C TYPES AND CLASSIFICATION

The WHO has classified FGM/C into four distinct types (see Table 3), with type III associated with the most

significant long-term morbidity (see Complications and Management) (Figs 3–11). To better delineate specific findings, the WHO has also included subtypes of FGM/C, categorized as Ia and Ib, IIa–IIc, and IIIa and IIIb (see Fig 12). However, the practice of FGM/C is not standardized, and physical findings may overlap between types and subtypes (see Figs 5 and 6). Type I FGM/C is classified as cutting of the glans or part of the body of the clitoris and/or prepuce; type II includes excision of the clitoris and labia minora, with or without excision of the labia majora; type III, infibulation, includes cutting and apposing the labia minora and/or majora over the urethral meatus and vaginal opening to significantly narrow it and may include clitoral excision (Figs 10 and 11); and type IV includes piercing, scraping, nicking, stretching, or otherwise injuring the external female genitalia without removing any genital tissue and includes practices that do not fall into the other three categories (Fig 13).

Prevalence of FGM/C subtypes is mainly influenced by ethnicity and region. Surveys of girls and women older than 15 years reveal that approximately 10% of cases are FGM/C type III, or infibulation, although these numbers are based on self-report and likely under- or

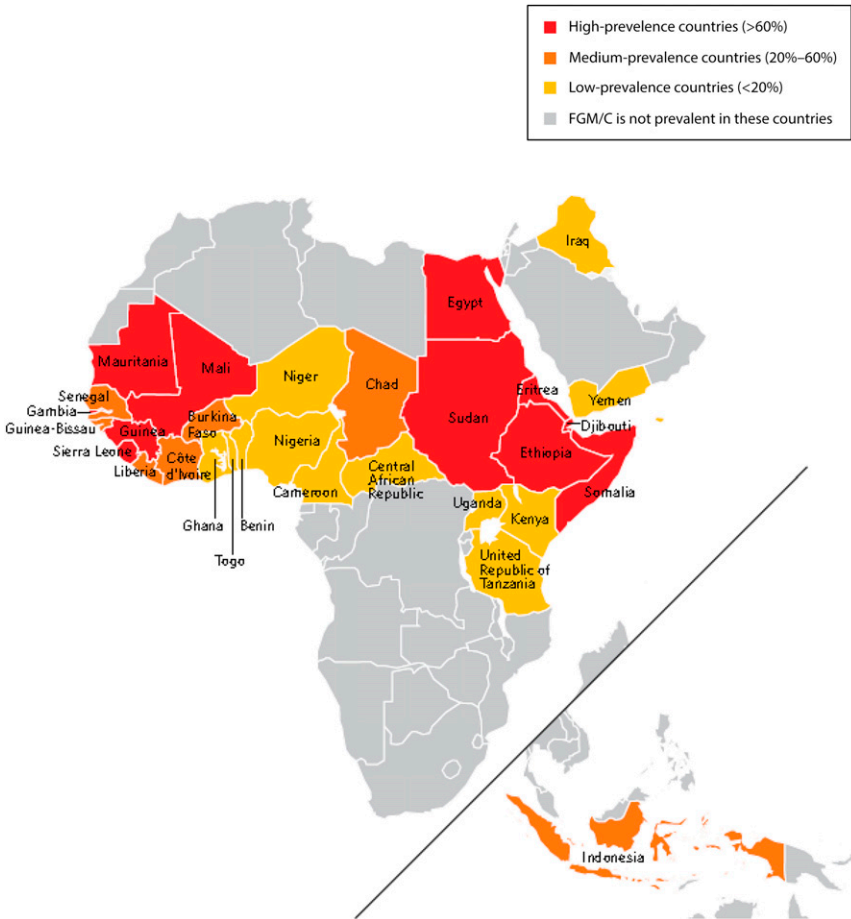


FIGURE 1
FGM/C global prevalence. Countries where FGM/C is practiced with unknown frequency and not pictured on this map include Oman, the United Arab Emirates, Bahrain, India, Malaysia, Russia, and Colombia.^{15–18} South Sudan seceded from Sudan in 2011 but is not noted on this map.¹⁰⁷ Reproduced with permission from United Nations Population Fund. *Demographic Perspectives on Female Genital Mutilation*. Copyright © United Nations Population Fund 2015.

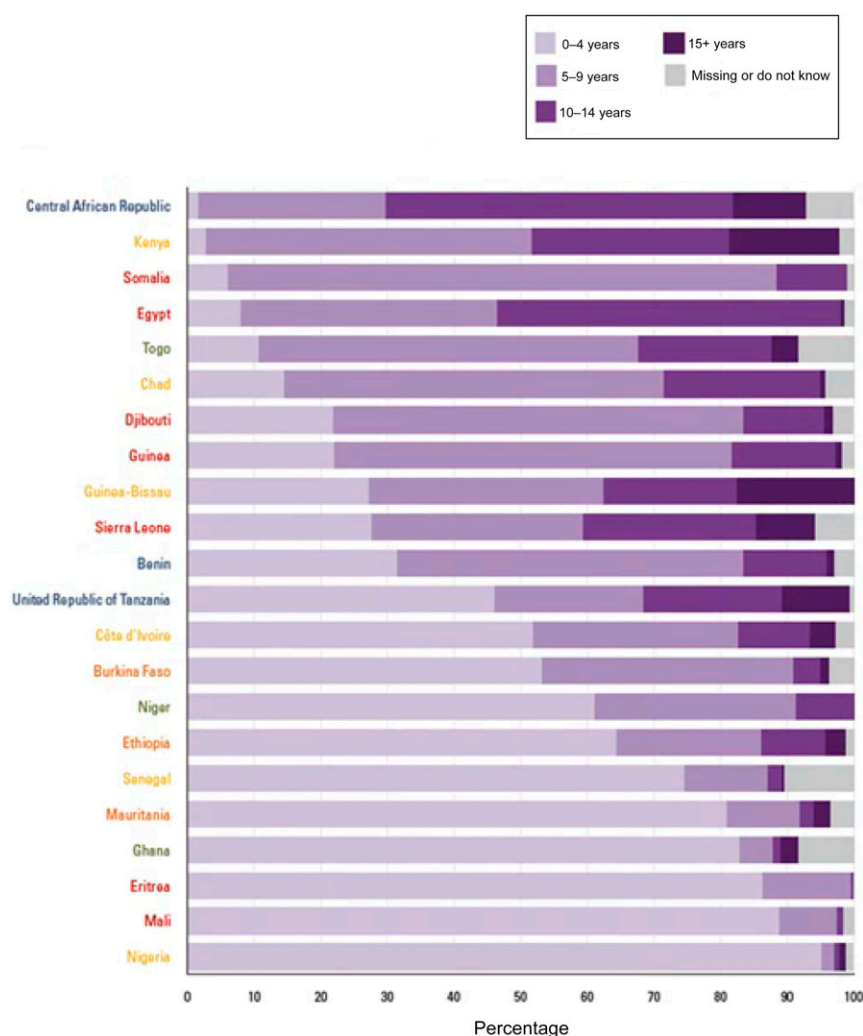


FIGURE 2

Maternal report of age that girls have undergone FGM/C, by country. Reproduced with permission from UNICEF. *Female Genital Mutilation/Cutting: A Statistical Overview and Exploration of the Dynamics of Change*. New York, NY: UNICEF; 2013:41. Copyright © United Nations Children's Fund 2013.

overestimate the actual prevalence of type III FGM/C.⁸ The practice of infibulation, the removal and apposition of the labia minora and/or labia majora with or without cutting of the clitoris, is concentrated in northeastern Africa in Djibouti, Eritrea, and Somalia. Data extrapolated from 2004 to 2008 East African regional surveys of girls and women 15 years and older revealed that 82% to 99% reported to have had undergone FGM/C, and of these cases, 34% to 79% were type III (Somalia having the highest prevalence of type III).²⁵

KNOWLEDGE OF, ATTITUDE ABOUT, AND PRACTICE OF FGM/C IN THE UNITED STATES

Knowledge of FGM/C is believed to be limited among US pediatric providers because there are no nationally required courses on diagnosis of type, management, or treatment of FGM/C for medical students, residents, or fellows in general pediatrics, family medicine, adolescent medicine, child abuse pediatrics, urology, or gynecology.^{9,26-28} Instead, existing studies from the United States are focused on nurse midwives and obstetricians and gynecologists and

note the lack of training in diagnosis, management, and cultural and legal aspects of care in adult women.²⁹⁻³² One recent US study revealed that of 79 general pediatricians surveyed, 73% had received no previous FGM/C education, 89% did not feel confident in their ability to identify FGM/C types, and frequency of performing external genital examinations on female patients at health supervision visits was inversely related to the age of the patient (with 75% performing examinations on infants, down to only 8% in 17- to 18-year-olds).²⁸ In literature from other high-income countries with immigrant populations from regions where FGM/C is prevalent, pediatricians have reported identifying FGM/C in pediatric patients, managing complications from remote and recent procedures, and, in some instances, being asked to perform FGM/C in children.^{9,33,34} However, one survey conducted in Australia revealed that of pediatricians surveyed, most reported neither discussing nor examining children for FGM/C.^{34,35}

CLINICAL HISTORY TAKING

For children with possible risk factors for FGM/C (eg, mother or sibling with a history of FGM/C, country of origin, birth country, and/or history of travel to a country where FGM/C is practiced), it is recommended that clinical assessment of FGM/C status be integrated into routine pediatric care. Nonetheless, it can be challenging. It is of utmost importance for the pediatric health care provider to establish a trusting relationship with the child or teenager and her family to allow for nonjudgmental questions and ongoing counseling. Experts suggest that health care providers ask the patient or parent the term they use to name female genital cutting. Use of the word mutilation is not recommended when discussing FGM/C with patients and

TABLE 2 Timeline of International Legislation Against FGM/C

Country	Year Legislation Enacted ^a
Benin	2003
Burkina Faso	1996
Central African Republic	1966, 1996 ^b
Chad	2003
Côte d'Ivoire	1998
Djibouti	1995, 2009 ^b
Egypt	2008
Eritrea	2007
Ethiopia	2004
The Gambia	2015 ¹⁰⁸
Ghana	1994, 2007 ^b
Guinea	1965, 2000 ^b
Guinea-Bissau	2011
Iraq (Kurdistan region)	2011
Kenya	2001, 2011 ^b
Mauritania	2005
Niger	2003
Nigeria (some states)	1999–2006
Senegal	1999
Somalia	2012
Sudan (some states)	2008–2009
Togo	1998
Uganda	2010
United Republic of Tanzania	1998
Yemen	2001

Reproduced with permission from United Nations Children's Fund. Female *Genital Mutilation/Cutting: A Statistical Overview and Exploration of the Dynamics of Change*. New York, NY: United Nations Children's Fund; 2013:9. Copyright © UNICEF 2013.

^a Bans outlawing FGM/C were passed in some African countries, including Kenya and Sudan, during colonial rule. This table includes only legislation that was adopted by independent African nations and does not reflect earlier rulings.

^b Later dates reflect amendments to the original law or new laws.

caregivers because it is potentially inflammatory and also difficult to translate (and may not be understood).

Given that girls who had FGM/C performed at a young age may not recall being cut (as well as the fact that parents or primary guardians may not reveal a history of FGM/C to their children), obtaining a history of FGM/C from the girl alone may yield little relevant clinical information. Instead, it is advisable that the FGM/C clinical history taking include both the girl and parent or guardian once rapport has been established. Similarly, some parents or guardians may not be aware that FGM/C performed in the country of origin before immigration is not prosecutable in the United States (see The Law and FGM/C in Minors in the United States) or may fear judgment from US medical providers, so they

may initially withhold information about previous FGM/C.

When caring for girls with or at risk for FGM/C, it is important to approach FGM/C discussion, physical examination, and counseling with cultural sensitivity. Girls' genitalia may have never been examined before, although they may have had multiple physical examinations in the United States or abroad.²⁸ Girls and mothers who have been cut may be afraid to seek care from a health care provider because of concerns about disapproval or previous negative experiences being used to teach trainees or other health care providers about FGM/C; many will seek a physician's care only if there is a health problem. Irrespective of their culture, girls' and mothers' knowledge of female anatomy, reproductive health, family planning, and sexually transmitted infections

may also be very limited.

Understanding each girl's and mother's current knowledge and perception of FGM/C, addressing fears, providing age-appropriate education about pelvic anatomy, and sharing information about the importance of the annual physical examination can facilitate ongoing rapport and engagement with health care. In addition, some girls or parents may request a female health care provider as well as a female interpreter. For girls at risk for FGM/C, it is advisable that efforts be made to honor this request, if at all possible, given social and cultural expectations.

It is important for health care providers to assess each patient individually and make no assumptions about her and her parents' beliefs regarding FGM/C. Mothers and fathers may or may not hold discordant views about FGM/C, and some clinical experts suggest that mothers who have themselves undergone FGM/C may nonetheless oppose subjecting their daughters to this practice. Instead, treating patients and caregivers with respect, sensitivity, and professionalism will encourage them to return and supports health-seeking behavior.

In families with risk factors for FGM/C, including having a mother and/or other girls who have already been cut in the family, it is advisable to inquire, in a nonthreatening manner, whether the parents are planning to perform FGM/C on their daughter. Raising such a sensitive topic may elicit various emotions, but this is a vital educational opportunity to reiterate child safety, the morbidity and mortality associated with FGM/C, and its legal consequences. Such discussions may occur over multiple visits, and it is recommended to revisit these discussions, particularly if the child is being seen before a trip to countries where FGM/C is still practiced. Whether to have this discussion in front of the girl depends on the developmental age of the child,

TABLE 3 FGM/C ICD-10 Coding and WHO Classification

FGM/C Type	ICD-10 Code ¹⁰⁹	WHO Classification (2016)
Female genital mutilation, unspecified	N90.810	
Female genital mutilation, type I	N90.811	Partial excision of the clitoris and/or prepuce
	—	Ia: removal of prepuce only
	—	Ib: partial or total ^a removal of clitoris and prepuce
Female genital mutilation, type II	N90.812	Partial or total ^a removal of the clitoris and labia minora, with or without excision of the labia majora
	—	IIa: removal of labia minora only
	—	IIb: partial removal of the clitoris and labia minora
	—	IIc: partial removal of the clitoris, labia minora and majora
Female genital mutilation, type III	N90.813	Infibulation: narrowing of the vaginal orifice by cutting and apposing the labia minora and/or labia majora over the vaginal opening; may include excision of the clitoris
	—	IIIa: removal and apposition of the labia minora
	—	IIIb: removal and apposition of the labia majora
Other female genital mutilation	N90.818	Unclassified (all other harmful procedures for non-medical purposes), including piercing
	—	IV

—, not applicable.

^a Although WHO classification describes total removal of the clitoris, it is the glans or the glans and part of the body of the clitoris that is cut.¹¹⁰

her degree of understanding, and the dynamics within the family. Encouraging parents to reevaluate this practice in a nonjudgmental manner and impressing on them that FGM/C causes medical complications, has no medical indications, and is also against the law (with associated legal consequences) will hopefully facilitate reconsideration of this practice. It is also essential to document these discussions in the medical chart so that health care

providers are both aware that education about FGM/C medical complications and illegality has been discussed and aware of what specific issues have and have not been discussed. Similarly, given that FGM/C performed overseas and before US emigration does not constitute a violation of US law, it is of utmost importance to document past history and timing of FGM/C in the chart so that it is clear that there are no legal ramifications for the family.

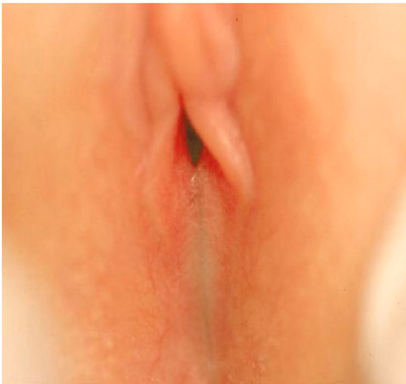

FIGURE 3
Prepubertal female with labial adhesions, no FGM/C. (Reprinted with permission from American Academy of Pediatrics. *Visual Diagnosis of Child Abuse on CD-ROM*. 3rd ed. Elk Grove Village, IL: American Academy of Pediatrics; 2008.)

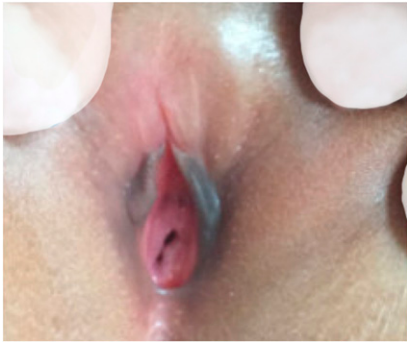

FIGURE 4
Periclitoreal adhesions, 18-month-old female patient, no FGM/C (photo credit: J.Y.).

EXTERNAL FEMALE GENITAL EXAMINATION: STANDARDS AND DOCUMENTATION

Bright Futures: Guidelines for Health Supervision of Infants, Children, and Adolescents, Fourth Edition, recommends that “each visit include a complete physical examination.” A complete physical examination includes assessment of genitalia from birth to age 21.³⁶

It is recommended that pediatricians and other health care providers include genital inspection as part of all health supervision examinations and be knowledgeable about the variants of normal genital anatomy and the signs of previous genital cutting.³³

The external genital examination in girls should include the identification of the prepuce, clitoris, and labia minora and majora (see Figs 14–16), and the examination should be performed in frog-leg position with chaperone use documented, per recommendations of the American Academy of Pediatrics.³⁷ In prepubertal girls, it may be more difficult to identify the clitoris, and in these cases, the prepuce may need to be partially retracted to facilitate

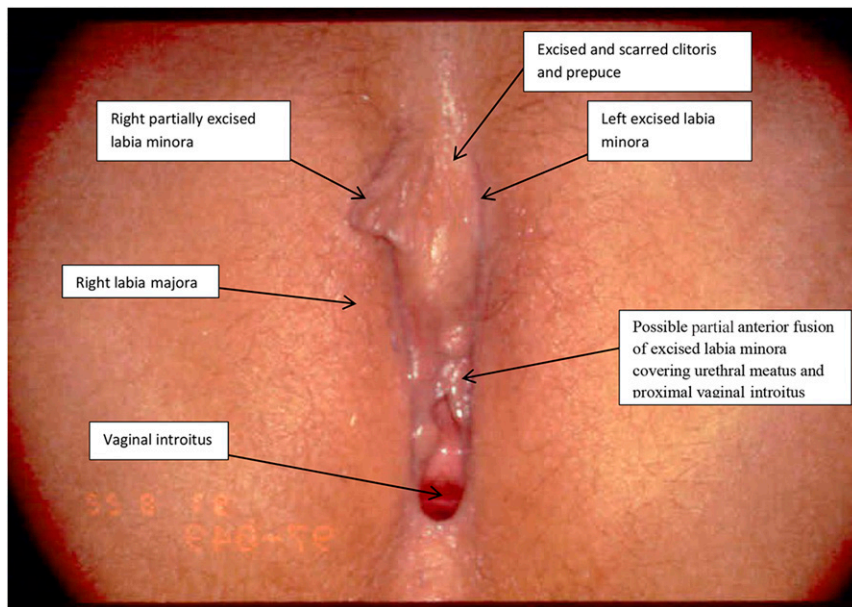


FIGURE 5

Type IIb or IIIa FGM/C in a prepubertal girl (excised clitoris, prepuce, partially excised right labia minora, absent left labia minora, and possible partial anterior fusion of excised labia minora covering urethral meatus and proximal vaginal introitus). This photo was reviewed by three FGM/C experts (J. Abdulcadir, C.J.A, and J.Y.), and consensus was either type IIb or IIIa. Arrows were added by J.Y. (Reprinted with permission from Graham EA. Ritual female genital cutting [RFGC] PowerPoint slides. 2014. Available at: <https://ethnomed.org/resource/ritual-female-genital-cutting-rfgc-powerpoint-slides/>. Accessed April 30, 2020.)

identification. Similarly, the labia minora is less developed, and it is advisable that efforts be made to identify this structure as well. Although not systematically studied, anecdotal experience by some experts suggests that types I, II, and IV FGM/C and even some type III subtypes may be difficult to recognize during the

physical examination, particularly in prepubertal girls. Similarly, prepubertal labial adhesions may be miscategorized as FGM/C (see Figs 3–6). If genital examination findings are equivocal for the presence of FGM/C and risk factors for FGM/C are present, a specialist trained in identification of FGM/C should be

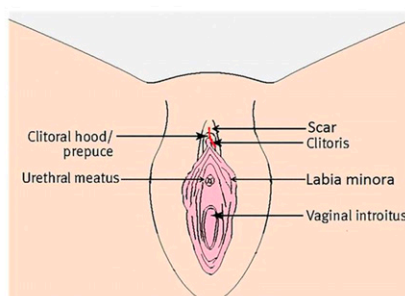
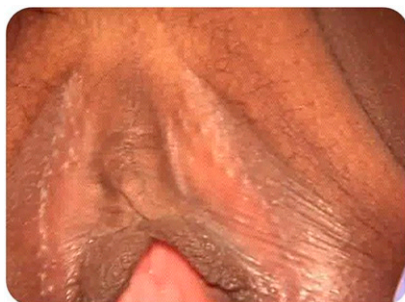


FIGURE 6

Type Ib FGM/C, scarring with excised clitoris and prepuce, or type IV FGM/C with linear scar from superficial cutting with adhesions, Tanner stage 5 female patient. This photo was reviewed by three FGM/C experts (J. Abdulcadir, C.J.A, and J.Y.), and it was unclear if it was type 1b or type IV on the basis of photos. The author of the source of the photo identifies the photo as type IV FGM/C. (Reprinted with permission from Creighton SM, Dear J, de Campos C, Williams L, Hodes D. Multi-disciplinary approach to the management of children with female genital mutilation [FGM] or suspected FGM: service description and case series. *BMJ Open*. 2016;6[2]:e010311.)

consulted, although currently, there are few such specialists in the United States (see Table 4 for a link to access regional specialists). However, given the subtleties of some FGM/C, it is assumed that not all cases will be identified.

If FGM/C is suspected to have occurred recently, it may also be difficult to confirm on physical examination without prompt evaluation by a specialist. The genitalia are highly vascularized tissues, healing occurs quickly, and less invasive cutting may easily be missed in some cases, given minimal or only subtle scarring.

If FGM/C is identified on examination, it is advisable that the clinician discuss findings with the caregiver and/or child if the child is old enough to participate in medical decision-making. Medical complications, depending on the type of FGM/C diagnosed, should be reviewed with the caregiver and/or child, as well as when to return for care if any of these complications develop (see Complications and Management). If an older child or teenager is unaware that she has had FGM/C performed (as may be the case if a girl had FGM/C performed at a young age), it is important that a culturally sensitive approach be taken to further discuss her diagnosis with her (see the Appendix for further guidance). Although not systematically studied, FGM/C is a community practice, and in some cultures, aunts, grandparents, or other figures of authority may make the decision to perform FGM/C on a child.³⁸ In these cases, theoretically, a parent may also not know of a child's previous FGM/C. It is suggested that a thoughtful, supportive discussion occur with the primary caregivers to inform them of the diagnosis, associated potential medical issues, and treatment, when clinically indicated. Given that such information may be distressing, it is advised to offer mental health

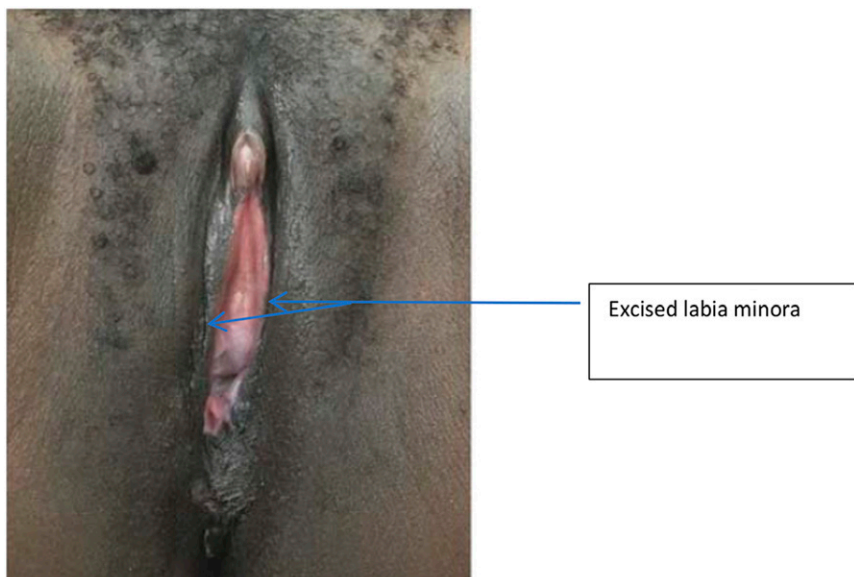


FIGURE 7

Type IIa FGM/C, excision of labia minora only, Tanner stage 5 female patient. (Reprinted with permission of Jasmine Abdulcadir. Copyright © Jasmine Abdulcadir. Also published in Abdulcadir J, Catania L, Hindin MJ, Say L, Petignat P, Abdulcadir O. Female genital mutilation: a visual reference and learning tool for health care professionals. *Obstet Gynecol.* 2016;128(5):959.)

professional support to caregivers, as indicated.

CODING AND DOCUMENTATION

The management of FGM/C should include complete documentation of clinical findings and use of the *International Classification of*

Diseases, 10th Revision (ICD-10) coding,³⁹ as indicated. A guide to ICD-10 coding and definitions and descriptions of FGM/C subtypes is provided in Table 3. In the future, appropriate coding will allow for better estimates of pediatric FGM/C prevalence. Additionally, clinical documentation of FGM/C findings

may facilitate timely referral to gynecologic or urologic specialists, if needed. However, a recent review of state-level hospital discharge data in Arizona revealed that from 2008 to 2014, only 243 cases of FGM/C had been documented, as identified by *International Classification of Diseases, Ninth Revision* and ICD-10 codes, and that of these 243 cases, none were documented in children younger than 18 years (C.J.A, unpublished observations). As context, the Population Reference Bureau estimates that 7459 women and children are at risk for FGM/C in Arizona, suggesting that FGM/C is not being documented consistently by health care providers.⁴⁰

COMPLICATIONS AND MANAGEMENT

Immediate Health Complications

Health care providers who work with children and live in countries with intermediate and high prevalence of FGM/C are likely to see immediate health complications; however, such a situation is likely rare in the United States.⁴¹ Exceptions will be newly arrived immigrants who underwent FGM/C just before entering the United States, girls who have recently returned to the United States after undergoing FGM/C while temporarily overseas, or FGM/C that has been performed in the United States. In general, medical complications become more severe with progression from type I to type III, tending to reflect the amount of tissue being removed. If the clitoral dorsal artery or labial branches of the pudendal artery are cut, hemorrhage has been documented in the range of 4% to 19%. Active hemorrhage, subsequent hypotension, hypovolemic shock, and death may occur in these cases.^{42,43}

Given the potential use of traditional nonsterile instruments, girls with FGM/C are at risk for acute infections. Girls with type III FGM/C most often have their legs bound for up to

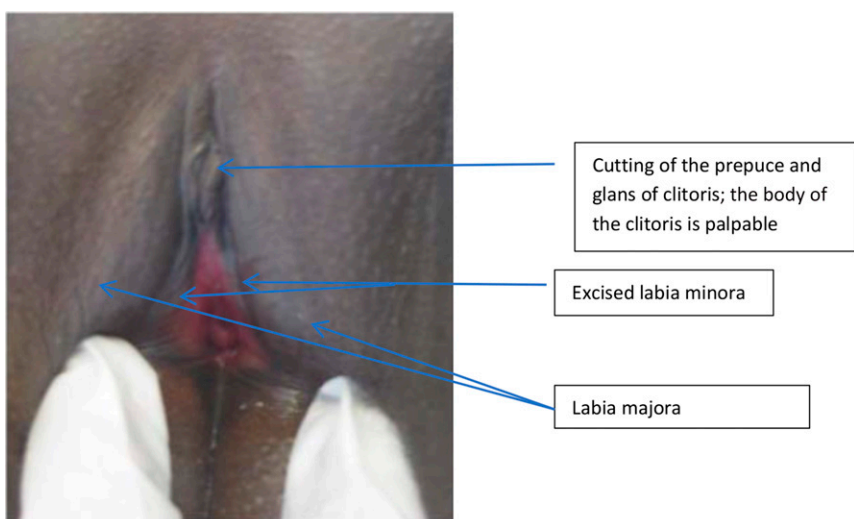


FIGURE 8

Type IIb FGM/C, partial or total clitoridectomy and excision of labia minora, Tanner stage 5 woman. (Reprinted with permission of Jasmine Abdulcadir. Copyright © Jasmine Abdulcadir. Also published in Abdulcadir J, Catania L, Hindin MJ, Say L, Petignat P, Abdulcadir O. Female genital mutilation: a visual reference and learning tool for health care professionals. *Obstet Gynecol.* 2016;128(5):959.)

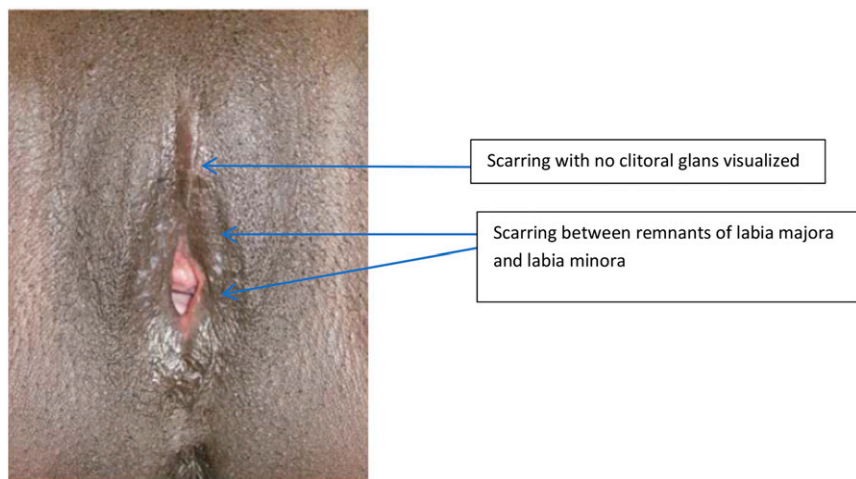


FIGURE 9

Type IIc FGM/C, partial or total clitoridectomy, excision of the labia minora and majora, Tanner stage 5 woman. (Reprinted with permission of Jasmine Abdulcadir. Copyright © Jasmine Abdulcadir. Also published in Abdulcadir J, Catania L, Hindin MJ, Say L, Petignat P, Abdulcadir O. Female genital mutilation: a visual reference and learning tool for health care professionals. *Obstet Gynecol.* 2016; 128[5]:959.)

1 week after cutting (standard practice in type III cases, reportedly to facilitate scar formation). Such prolonged binding facilitates bacterial overgrowth and prevents wound healing. Girls may suffer from cellulitis or wound abscesses; gangrene, septic shock, and tetanus

have also been reported. Difficulty urinating, both from pain and deliberate decreased liquid intake, is common.⁴¹ The urethra, vagina, and/or rectum may also be inadvertently cut during FGM/C. Fractures of the clavicle, femur, or humerus also have been reported, resulting from the

need to restrain a girl who was not anesthetized during the procedure⁴² (Table 5).

If a girl is seen with any immediate complications, it is recommended that the health care provider refer for appropriate emergency care and the patient receive vaccination against tetanus. Once stabilized, it is recommended to consult a health provider with FGM/C expertise (see Table 4) to determine the need for medical and/or surgical management. Although there are no data that directly link FGM/C to acquisition of HIV, hepatitis B, or hepatitis C, some clinical experts recommend testing for these infections at the initial visit and at least 6 months after cutting has occurred.⁴⁴ As in all children, it is advised that hepatitis B vaccination be offered to girls with FGM/C if they are neither immune nor infected.

In cases in which a girl has been recently cut, it is recommended to offer mental health supports for her, as indicated. Refer to Reporting Child Abuse and Ethical Analysis regarding scenarios in which child abuse reports are recommended.

Long-Term Complications

Studies reveal that girls and women with type III FGM/C are also at higher risk of long-term health complications than those with type I, II, or IV FGM/C. A systematic review of the literature reveals that long-term health complications include dysmenorrhea as well as psychosexual, infertility, and urinary problems.⁴² However, physical and psychological complications are not necessarily proportionate to the FGM/C type. Although the authors of one study state that the relative risk of obstetric complications (including increased cesarean delivery rates), of the need for infant resuscitation, of stillbirths, and of infants with low birth weight increases with the severity of FGM/C, data are limited, and it is likely that the combination of obstructed labor and substandard

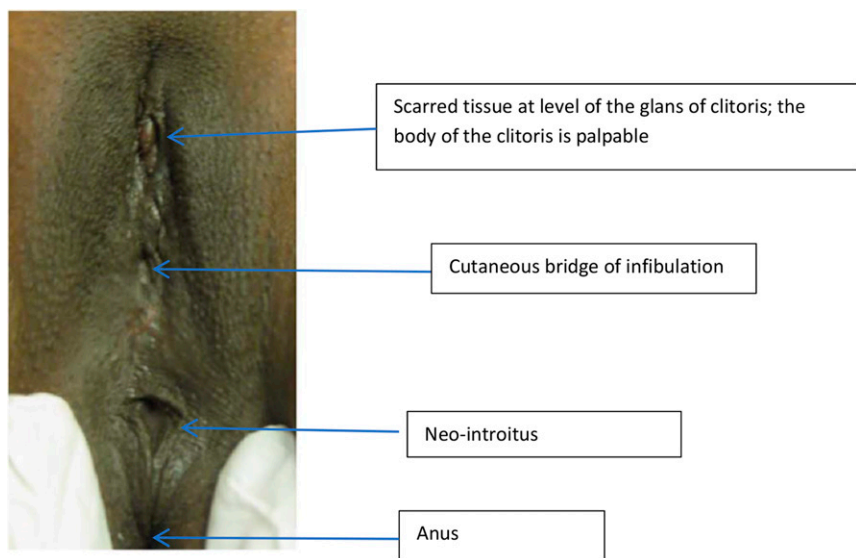


FIGURE 10

Type IIb FGM/C, with significant narrowing of the introitus from stitching of the labia minora, Tanner stage 5 woman. (Reprinted with permission of Jasmine Abdulcadir. Copyright © Jasmine Abdulcadir. Also published in Abdulcadir J, Catania L, Hindin MJ, Say L, Petignat P, Abdulcadir O. Female genital mutilation: a visual reference and learning tool for health care professionals. *Obstet Gynecol.* 2016; 128[5]:961.)

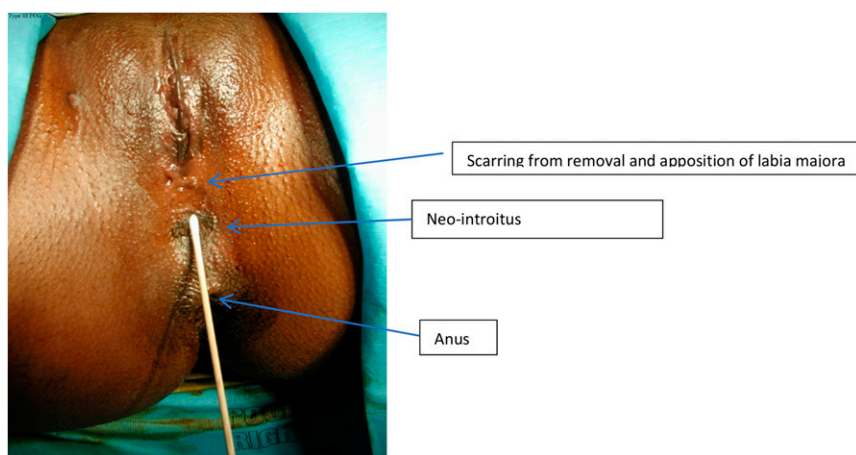


FIGURE 11

Type IIIb FGM/C in a Tanner stage 5 17-year-old with severe dysmenorrhea preventing her from going to school during menstrual flow (photo courtesy of N.N.).

health care systems contribute to such complications (Tables 6 and 7).⁴⁵

Secondary analysis of cesarean delivery rates has revealed that health care provider unfamiliarity with defibulation and/or other management options for FGM/C may increase the risk of cesarean deliveries in some cases.^{46,47}

Long-term complications can be placed into 7 major categories: pain, urinary issues, infections, scarring, infertility, sexual dysfunction,^{42,48} mental health issues,^{49,50} and other (Table 5).

Pain

Pain is a common long-term complication after type III FGM/C and can also be present in patients with type I and II FGM/C. In type III FGM/C, the narrow neo-introitus creates a closed environment that can obstruct urinary and menstrual flow. Because of the scarring that obstructs the introitus, the menstrual flow of women and teenagers with infibulation can last longer than usual, rendering them unable to go to school during this time (see Fig 11). Menstruation may be painful and may become dark and foul smelling because of the retention of blood. In

very rare cases, hematocolpos and hematometra have been documented.

Other painful complications arise when remnant foreign bodies are left in the scar during the initial procedure. These can produce sharp pains when sitting and walking. Cut or trapped nerve fibers have also been documented, creating very painful neuromas. In both of these situations, defibulation and removal of the foreign body or neuroma are recommended.⁵¹

Dyspareunia in sexually active teenagers with type III FGM/C has been seen (see Future Infertility) and treatment includes defibulation.⁵²

One study followed 40 Somali women whose primary indications for defibulation were pregnancy (30%), dysmenorrhea (30%), apareunia (20%), or dyspareunia (15%). Of the 32 patients surveyed, 94% stated they would highly recommend defibulation to others; 100% of patients were pleased with the results, felt their appearance had improved, and were sexually satisfied, suggesting that the symptoms of teenagers who have undergone FGM/C and are experiencing dysmenorrhea will also be improved by defibulation.⁵²

Urinary Issues

The narrow neo-introitus and scar in type III FGM/C create a dark, moist, and unventilated area surrounding the urethra. Urine can stagnate beneath the scar and promote abnormal bacterial growth. As a result, girls who are infibulated can experience chronic urinary tract infections. With recurrence of UTI, suppressive antimicrobial medication is an option, although defibulation is preferable; however, currently there are no known systematic studies evaluating the efficacy of prophylactic antibiotic treatment or defibulation in preventing recurrent UTIs associated with FGM/C.⁵³

In general, clinical experience indicates that girls who are infibulated may describe their urinary stream as being slow and having a dripping quality. As the urine exits the urethra, it trickles under the scar and then drips past the neo-introitus. Patients also may complain of overactive bladder on the one hand or straining and urinary retention on the other. These issues may be attributable to injury of the urethra, resulting in urinary strictures and stenosis and requiring cystoscopy or urethral dilation. It is also possible for the obstructing scar to enable urinary crystals to deposit and, as a result, form urinary stones.⁵⁴ These patients routinely experience sharp pains and require defibulation for stone removal.

Scarring and Other Postinflammatory Reactions

Keloid formation is rare, although not unknown in FGM/C cases. The main problem with the infibulated scar is its obstructive nature. However, other complications in type II FGM/C include unintended labial fusions and cysts (fluid-filled, sebaceous, or inclusion cysts or abscesses). There are multiple case reports documenting epidermal cysts associated with all types of FGM/C.

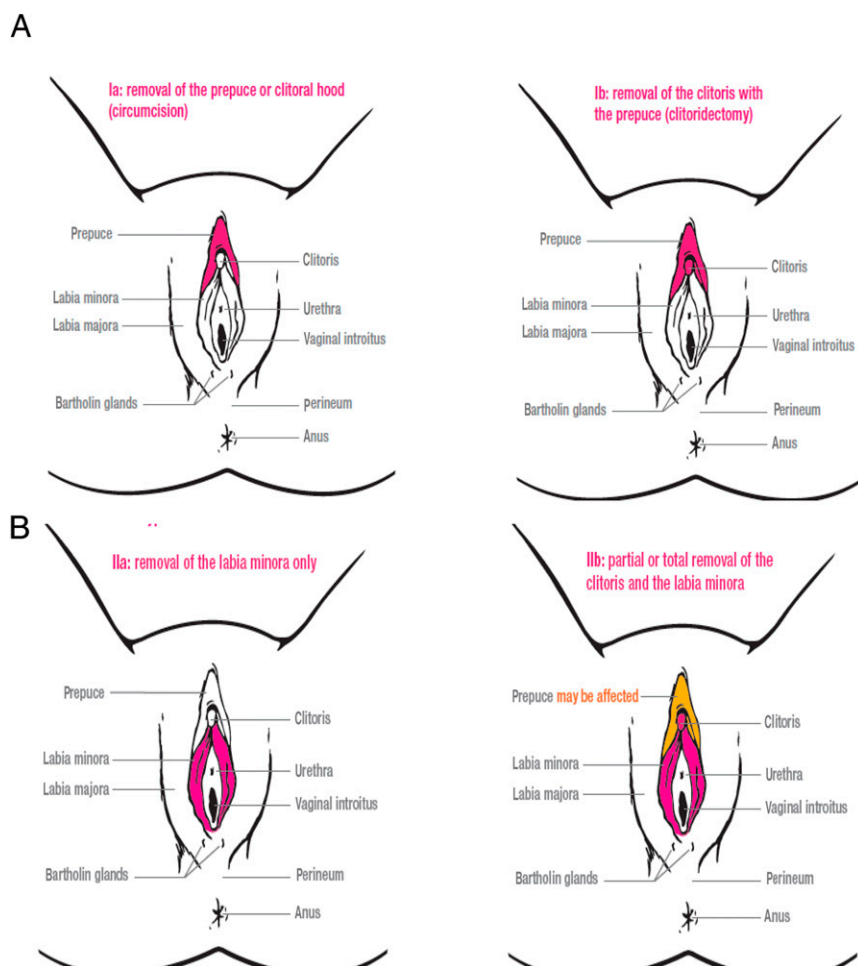


FIGURE 12

WHO FGM/C subtype diagrams. A, Female genital mutilation (FGM) type 1. B, FGM type 2. World Health Organization. Copyright © World Health Organization 2016. Also published in Abdulcadir J, Catania L, Hindin MJ, Say L, Petignat P, Abdulcadir O. Female genital mutilation: a visual reference and learning tool for health care professionals. *Obstet Gynecol.* 2016;128(5):959–960.

Some cysts have been documented to grow up to 12 cm in size and are not only extremely painful but also become problematic for ambulation and sitting.^{55,56} Dissecting the cyst and defibulating the patient is necessary in these cases (see Fig 17).

Other Infections

Given the infibulated scar, this enclosed environment fosters bacterial and fungal growth and predisposes girls to chronic or recurrent vaginal infections. In these cases, oral antifungal and antimicrobial medications are recommended. If the patient's neo-introitus is not too small and she is comfortable with introducing vaginal

suppositories, this is an alternative treatment. For girls and teenagers with chronic infections, defibulation by an adolescent or general gynecologist experienced with managing FGM/C is recommended.

A study in rural Gambia of teenagers and women (15–54 years) with clinically diagnosed type I or II FGM/C ($N = 671$) also revealed a higher prevalence of bacterial vaginosis and herpes simplex virus 2 compared with teenagers and women without FGM/C but did not reveal an increased risk for perineal or anal damage, vulvar tumors, dyspareunia, infertility, organ prolapse, or other reproductive tract infections.⁵⁷

Of note, large epidemiologic studies conducted in low- or middle-income countries where both FGM/C and HIV and/or hepatitis B are prevalent have not revealed an association between FGM/C and HIV and/or hepatitis B infections.^{44,58,59} The authors of these studies did not evaluate risk around the time of cutting but months to years after the cutting occurred. To our knowledge, no studies have specifically addressed hepatitis C infection risks. However, given that FGM/C is often performed with unsterile equipment that may be shared between patients, some experts recommend testing girls with FGM/C for these blood-borne infections.

Future Infertility

Infertility for women with type III FGM/C is influenced by anatomic and psychological barriers as well as from possible recurrent gynecologic infections. In a Sudanese case-control hospital-based study of 99 women without hormonal, iatrogenic, or male-partner risk factors for infertility a diagnostic laparoscopy was performed, and it was found that primary infertility was associated with the increased anatomic damage inflicted by FGM/C.⁶⁰ Repeated attempts at penetration through the infibulated scar may be painful and difficult, and stretching of the infibulated introitus may take months. The learned association between sexuality and pain may have a significant negative effect on the woman's willingness to have intercourse and, thereby, on fertility. In general, if there are any issues related to FGM/C that negatively affect sexual health, referral to appropriate mental health supports is advisable for both women and their partners.

Sexuality

There are currently no studies that have been specifically focused on sexuality in teenagers with FGM/C. The impact of FGM/C on female

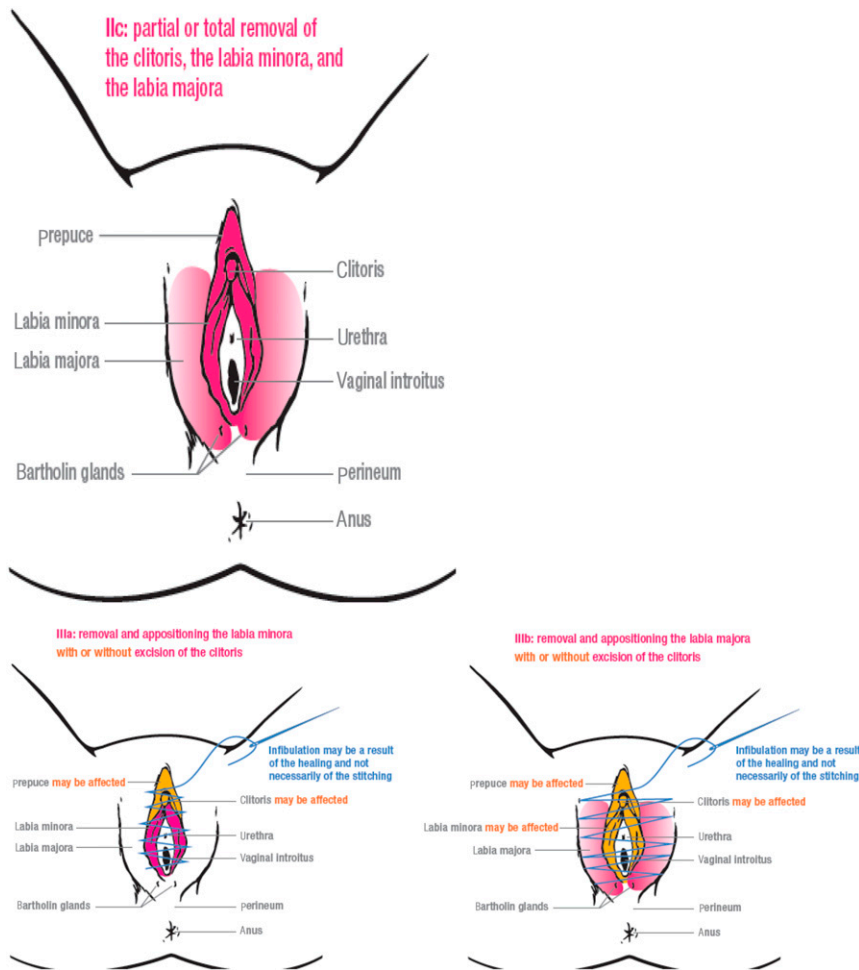


FIGURE 12
Continued.

sexuality has been evaluated in a few studies in adult women. However, the lack of standardization of FGM/C subtype studied and the use of nonvalidated questionnaires make interpretation of results difficult. Some studies reveal that women with FGM/C have reported less sexual desire, arousal, orgasms, and satisfaction compared with women without FGM/C⁶¹ as well as increased rates of dyspareunia.⁶² Other research has revealed no association between FGM/C and sexual intercourse frequency and that women with FGM/C also initiated sexual intercourse more than women without FGM/C.^{63,64}

Surgical clitoral reconstruction is an emerging area of study. However, to

date, there are no conclusive results revealing long-term benefits. If teenagers inquire about the option of reconstructive surgical repair, it is important to review the fact that there is still inadequate data that assure successful outcomes, including a decrease in pain and increased sexual pleasure.^{65,66}

Mental Health

There has been limited high-quality research on the effects of FGM/C on the mental health of girls and women. One 2010 systematic review of the literature included 17 studies of women with and without FGM/C ($N = 12\,755$) and revealed insufficient evidence to support or refute the link of FGM/C to specific mental health diagnoses.⁴⁸ In a more recent 2017

small cross-sectional study of Egyptian women and girls ($N = 204$, ages 14–19 years), those with and without FGM/C were compared, and a significantly higher prevalence of somatization, depression, and anxiety was found in those with FGM/C.⁴⁹

Defibulation

Defibulation, also known as deinfibulation, is the procedure that opens the infibulated scar in type III FGM/C and exposes the vaginal introitus and urethral opening. In general, in some regions of the world, including Djibouti, defibulation is most often performed in newly married teenagers by a traditional birth attendant or midwife so that sexual intercourse may occur. In other regions, including North Sudan, Somalia, and areas in southern Egypt, the husband opens the neo-introitus over time through ongoing attempts at penetration. However, some teenagers and women who have access to medical care may have defibulation performed by a medical professional at marriage or after their official engagement.

Teenagers who are infibulated may present to health care providers requesting defibulation. Given the significant morbidity associated with type III FGM/C, experts believe that defibulation should be recommended for all girls and teenagers with type III FGM/C, particularly when complications are currently present. Similarly, teenagers who are pregnant should also be counseled regarding risks during and after pregnancy and should be strongly encouraged to undergo defibulation.

Of note, given that girls and teenagers who are infibulated have varying degrees of obstruction of urinary or menstrual flow, have varying degrees of pain, and/or have risks for normal vaginal delivery, such signs and symptoms should underscore the medical necessity for treatment. Given the medical necessity of

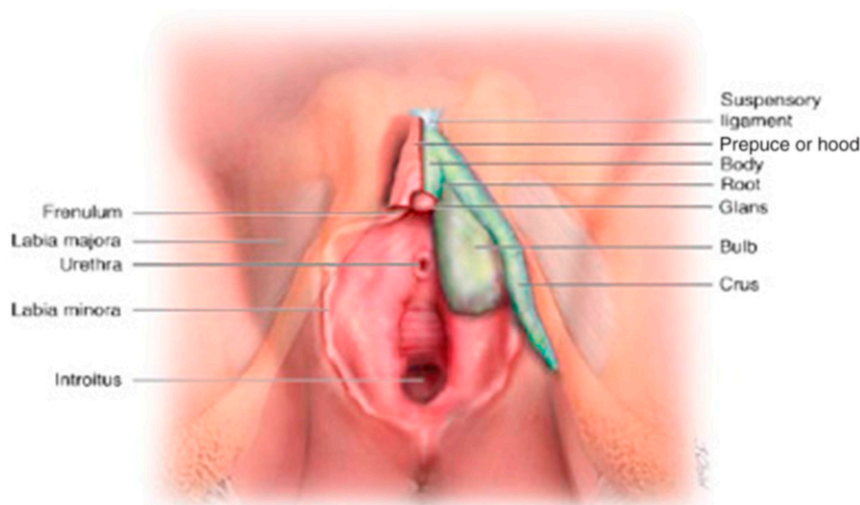

FIGURE 13

Female genital anatomic structures. Clitoral excision refers to the cutting of the glans (which is the distal part of the body of the clitoris) or the glans and part of the body. In all cases, part of the clitoral body remains intact, with scarring overlying the remaining body. The bulbs and crura, two other sexual erectile structures, have not been noted to be affected in FGM/C cases. Reprinted with permission from Abdulcadir J, Botsikas D, Bolmont M, et al. Sexual anatomy and function in women with and without genital mutilation: a cross-sectional study. *J Sex Med.* 2016;13(2):227–237 and Pauls RN. Anatomy of the clitoris and the female sexual response. *Clin Anat.* 2015;28(3):376–384.

treatment in these cases, Medicaid should cover the defibulation.

In all cases of defibulation, it is advised that an experienced pediatric gynecologist (for young children), gynecologist (for older children and teenagers), urologist, or urogynecologist be identified to perform the procedure. One challenge

is that there are currently few trained specialists with experience in managing FGM/C, particularly in young children. Similarly, it may be difficult to refer a girl or teenager to a male provider, and much discussion and support will need to be provided to facilitate successful care. Counseling patients who do not want to be defibulated, despite current complications, may be challenging given social and cultural pressures. This counseling may take multiple

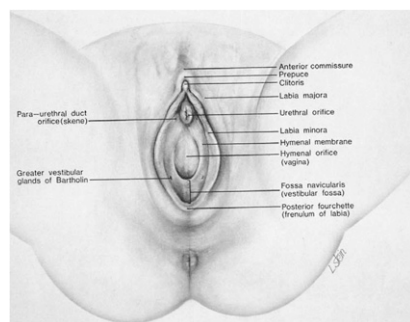


FIGURE 14

Normal prepubertal female anatomy. Labia minora is often less well-developed than pictured in prepubertal girls.¹¹⁰ (Reprinted with permission from Graham EA. Ritual female genital cutting [RFGC] PowerPoint slides. 2014. Available at: <https://ethnomed.org/resource/ritual-female-genital-cutting-rfgc-powerpoint-slides/>. Accessed April 30, 2020.)

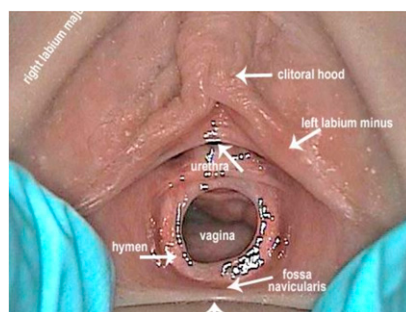


FIGURE 15

Prepubertal female introitus. (Reprinted with permission from American Academy of Pediatrics. *Visual Diagnosis of Child Abuse on CD-ROM*. 3rd ed. Elk Grove Village, IL: American Academy of Pediatrics; 2008.)

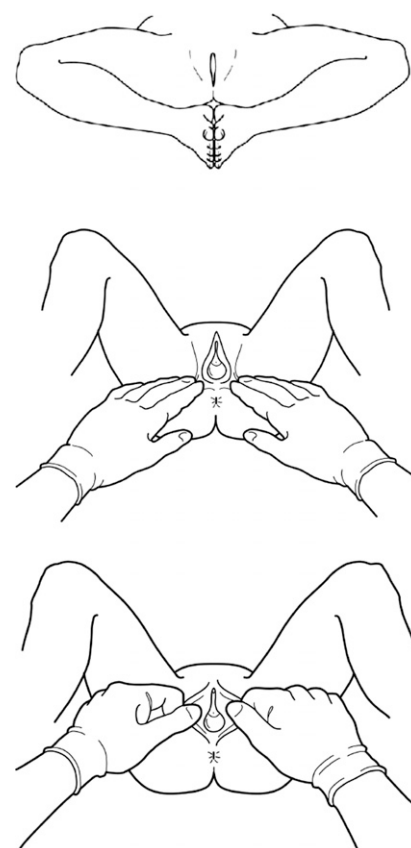


FIGURE 16

Clinical approach to external female genital examination. (Reprinted with permission from American Academy of Pediatrics. *Visual Diagnosis of Child Abuse on CD-ROM*. 3rd ed. Elk Grove Village, IL: American Academy of Pediatrics; 2008.)

visits, and it may be necessary to dispel fears of loss of virginity in cases of defibulation.⁶⁷ Mental health and social issues may arise and need to be addressed through counseling and support. Multiple legal and ethical issues may also arise in cases in which a teenager desires defibulation but she does not want her parents to know because of fear of stigma and/or refusal by her parents (see The Law and FGM/C in Minors in the United States, Ethical Analysis, and Case 2 in the Appendix for further information).

For young children who are defibulated, general anesthesia is recommended in all cases.

If a teenager is pregnant, defibulating her under spinal anesthesia during

TABLE 4 Resources

Title or Description	Source
<i>Care of Girls and Women Living with Female Genital Mutilation: A Clinical Handbook.</i>	WHO ¹¹¹
To find a regional FGM/C expert, please go to the US End FGM/C Network Web site	https://endfgmnetwork.org/
Female Genital Mutilation/Cutting: Existing Federal Efforts to Increase Awareness Should Be Improved	US Government Accountability Office ¹¹²
<i>WHO Guidelines on the Management of Health Complications From Female Genital Mutilation</i>	WHO ¹¹³
Eliminating Female Genital Mutilation: An Interagency Statement: OHCHR, UNAIDS, UNDP, UNECA, UNESCO, UNFPA, UNHCR, UNIFEM, WHO	WHO ²
Female Genital Mutilation/cutting: A Statistical Overview and Exploration of the Dynamics of Change	United Nations Children's Fund ¹⁶
Female Genital Mutilation (FGM) Frequently Asked Questions	United Nations Population Fund ¹¹⁴
Background information and educational pamphlets in Amharic, Arabic, French, Somali, Swahili, and Tigrinya	US Citizenship and Immigration Services ¹¹⁵
Guidelines for the US Domestic Medical Examination for Newly Arriving Refugees	Centers for Disease Control and Prevention ¹¹⁶
Immigrant Child Health Toolkit	American Academy of Pediatrics ¹¹⁷
Female Genital Mutilation. A Visual Reference and Learning Tool for Health Care Professionals	Abdulcadir et al ¹¹⁸ ; video available at https://www.youtube.com/watch?v=XRid7jUzMY
Defibulation: A Visual Reference and Learning Tool	Abdulcadir et al ⁶⁸
<i>Female Genital Mutilation/Cutting and Violence Against Women and Girls: Strengthening the Policy Linkages Between Different Forms of Violence</i>	United Nations Entity for Gender Equality and the Empowerment of Women ¹²
Overview: Female Genital Mutilation (FGM)	National Health Service ¹¹⁹
Female genital mutilation (FGM): Resources for Healthcare Staff	National Health Service, Department of Health and Social Care ¹²⁰
FGM: Mandatory Reporting in Healthcare	National Health Service, Department of Health and Social Care ¹²¹
Canadian FGM/C statement	Canadian Paediatric Society ¹²²
Australian FGM/C statement	The Royal Australasian College of Physicians ^{123,124}
New Zealand FGM/C statement	The FGM Education Programme ¹²⁴

the second trimester is advised. In countries where spinal anesthesia may not be available, local anesthesia may be used, if necessary. This allows ample time for healing and will facilitate providing care during labor. However, some teenagers may present late in the third trimester. They can still be defibulated up to 34 weeks' gestation, which will allow for the neo-vulva to heal adequately before labor. Otherwise, defibulating the patient preferably in the first stage of labor or when the baby is crowning are options and are the routine approaches in some African countries, although these approaches have not been systematically studied. Defibulation in the first stage of labor does facilitate pelvic examinations, catheterization, and general monitoring during labor while also allowing for procedures on less edematous tissues and quicker delivery. If a teenager is not pregnant, she can be defibulated under regional or general anesthesia. Although the

WHO recommends local anesthesia as best practice, this recommendation is not based on strong evidence. Local anesthesia is not recommended (unless in a country where spinal and general anesthesia may not be available),⁶⁸ because women may report flashback memories from the day when they were cut, as noted in one case report.⁶⁹

For type III FGM/C, timing and complications of defibulation have not been systematically studied in prepubertal girls. For prepubertal girls with complications, including pain, obstruction of urinary stream, and recurrent urinary tract infections, and teenagers with dysmenorrhea related to FGM/C, it is important that the health care provider begin conversations with the parents and/or child regarding the need for defibulation to treat these medical complications and associated morbidity as well as whether the girl would benefit from mental health counseling.

COMMUNITY ENGAGEMENT

Within the United States, emerging evidence indicates a misunderstanding and distrust among immigrant communities with fears of deportation, criminalization, raids by Immigration and Customs Enforcement, and fear of being reported to Child Protective Services (CPS).⁷⁰⁻⁷⁴ Some health care and social service providers may also not understand the long-term physical and mental health-related morbidity associated with the practice of FGM/C.⁷⁵ In addition, language barriers may complicate patient-provider communication and have been demonstrated to negatively affect health-seeking behavior and health services use.^{30,76,77}

A grassroots community-based and community-led approach is essential when working with affected populations to ensure that policies, preventive interventions, and advocacy are all informed by the perspectives, experiences, and needs

TABLE 5 FGM/C Immediate and Long-Term Complications

Immediate Complications		Long-term Complications	
Category	Description	Category	Description
Bleeding	Hemorrhage ⁴¹	Urinary	Urethral strictures ⁴¹
	Anemia		Meatal obstruction ⁴¹
	Hypotension		Chronic urinary tract infection ¹²⁵
	Hypovolemic shock		Pyelonephritis
	Death ⁴¹		Meatitis
Infection	—	Infection	Urinary crystals
	Cellulitis		Chronic yeast infections
	Abscess ⁴¹		Chronic bacterial vaginitis ⁴¹
	Fever ⁴¹		Herpes simplex virus
	Pelvic inflammatory disease		Vulvar or periclitral abscess ⁴¹
	Tetanus		No definitive data on risks for hepatitis B, hepatitis C, or HIV ^{44,126}
	Gangrene		—
	Septic shock		—
	Poor healing ⁴¹		—
	—		—
Oliguria	Dehydration	Scarring	Fibrosis ⁴¹
	Urethral injury ⁴¹		Keloids ⁴¹
	Urethral edema ⁴¹		Partial fusion
	Urinary retention ⁴¹		Complete fusion
	—		Hematocolpos ⁴¹
Fractures	—	Pain	Inclusion or sebaceous cyst ⁴¹
	Clavicle		Neuromas
	Femur		Chronic vaginal infections ⁴¹
	Humerus	Infertility	Dyspareunia ⁴¹
	—		Vaginismus
	—		Dysmenorrhea ⁴¹
	—		Vaginal stenosis
	—		Infibulated scar
	—		Dyspareunia ⁴¹
	—		Aporeunia
	—	Mental health	Anxiety disorders ^a
	—		Depression ^a
	—		Posttraumatic stress disorder ^a
	—		Somatisation ^a

—, not applicable.

^a Large systematic studies are lacking. Some small studies have revealed an association between FGM/C and mental health diagnoses.⁴⁹

of those directly affected by FGM/C.⁷⁸ There are varying approaches to engage FGM/C-affected communities that need to be culturally and linguistically tailored on the basis of availability of local expertise, resources, infrastructure, and

personnel. It is important to assess whether local efforts already exist because it will be much easier to build and/or expand on these partnerships. If there are no preexisting relationships, new community-based partnerships may

need to be explored and created. It is recommended that pediatric health care professionals nurture meaningful partnerships with FGM/C-affected communities to foster greater trust, open dialogue, counseling, education, and community outreach to enhance culturally sensitive care for affected populations and to prevent FGM/C among female minors. In the past, the focus of outreach efforts has principally targeted women, who have been at the forefront of the perpetuation of FGM/C. However men, as husbands, fathers, brothers, sons, community leaders, and religious figures, also play a critical role in changing social norms; encouraging greater dialogue with

TABLE 6 Obstetric Difficulties in Type III FGM/C

Obstetric Difficulties
Prolonged labor
Increased risk of perineal tears or episiotomy
Perineal wound infection
Difficult episiotomy repairs
Postpartum hemorrhage
Sepsis
Difficulty placing fetal scalp electrode, Foley catheter, or intrauterine pressure catheter
Difficulty performing fetal scalp pH

Adapted from Nour NM. Female genital cutting: clinical and cultural guidelines. *Obstet Gynecol Surv*. 2004; 59(4):272–279.

TABLE 7 Perinatal Complications of FGM/C

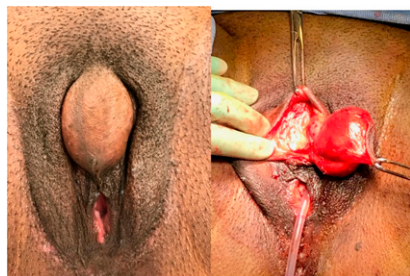Perinatal Complications
Increased cesarean deliveries
Stillbirth
Low birth wt (data inconclusive) ^a
Increase rates of infant resuscitation

Adapted from Banks E, Meirik O, Farley T, Akande O, Bathija H, Ali M; WHO Study Group on Female Genital Mutilation and Obstetric Outcome. Female genital mutilation and obstetric outcome: WHO collaborative prospective study in six African countries. *Lancet*. 2006; 367(9525):1835–1841.

^a One recent multicenter prospective study in the Gambia revealed no association between FGM/C and infants with low birth wt but a statistically significant increased risk of perinatal death and need for infant resuscitation ($n = 1208$).¹²⁷

and engagement of their wives, daughters, and sisters in health services use; and supporting efforts toward eventual abandonment of the practice of FGM/C.^{77,79} Consequently, it is critically important to include both men and women in strategies to enhance health services use and improve experiences with care while supporting community-wide FGM/C prevention efforts.

It is advisable that clinicians seek to engage within and across health care systems and multispecialty provider teams instead of staying within isolated profession-specific silos. Such multidisciplinary teams may comprise child abuse specialists, gynecologists, urologists, and general surgeons in addition to nurses, social workers, teachers, psychologists, counselors, case managers, certified

**FIGURE 17**

Type IIb FGM/C with large cyst, Tanner stage 5 female patient (photo courtesy of N.N.).

medical interpreters, patient navigators, community health workers, refugee resettlement agencies, and public health departments. In addition, culturally appropriate and language-congruent resources, such as written information on FGM/C, should be made available in health care settings in the form of posters, pamphlets, or leaflets placed in private areas, such as women's restrooms, and made available in relevant languages.

Since 2015, mandatory reporting legislation in the United Kingdom has come under increased scrutiny for the lack of consistent, reliable, high-quality data as well as for the lack of a routine system of monitoring.^{80–83} Stigmatization of FGM/C-affected communities and distrust of law enforcement have resulted in underreporting, along with a lack of professional awareness and training.⁸⁴ Within the context of migration, the impact of acculturation, education, and length of stay on changing attitudes toward the practice are critical considerations when determining girls at risk for FGM/C.^{85–87} The first dedicated multispecialty clinic in the United Kingdom for girls affected by FGM/C and girls at risk with complex health needs uses a pediatric child abuse expert, a pediatric adolescent gynecologist with expertise in FGM/C, a child psychotherapist, and a specialist nurse in pediatric and adolescent gynecology, along with interpreters.³³ Referrals to this dedicated clinic are evaluated promptly with genital as well as colposcopy examinations, followed by further testing, counseling, and engagement of additional social and legal support services, as needed.

It is advised that attention also be paid to ensuring that the next generation of health care providers and scholars gain critical skills and exposure to culturally appropriate approaches to care for this population

during their training. Hence, students, including medical and nursing students, residents, and fellows across various health, social science, and public health professions, should also be engaged in clinical care, counseling, education, and community outreach on FGM/C in such a way that is respectful of patients, caregivers, and communities. Models of established training guidelines and evidence-based educational competencies specific to FGM/C are lacking across all levels of health professions training. A proposed approach to instituting clinician competencies includes convening a multidisciplinary team of experts comprising key stakeholders from clinical medicine, medical education, public health, and research. Their expertise in competency development processes as well as in FGM/C would address FGM/C-specific knowledge and skills for clinical practice, patient care and handling ethical conundrums, communication skills, interprofessional collaboration (including partnering with community activists), and prevention efforts engaging individual families as well as FGM/C-affected communities.³² Thereafter, evaluative performance metrics could be used to assess whether clinician competencies and patient care outcomes are being optimized. Moreover, an integrated team-based approach to health care delivery may more effectively address the multidimensional facets of providing holistic care, recognizing the intersection of ethnicity, migration, sex, and gender, which underlies the social construct of FGM/C.⁸⁸ Efforts to directly engage FGM/C-affected communities to engender trust, educate, promote continuity of care, and empower women and girls may enhance their health literacy and self-efficacy in seeking care for FGM/C-related concerns, navigating the health care system, and preventing future FGM/C.

ETHICAL ANALYSIS

Some have attempted to defend FGM/C by an appeal to cultural relativity, noting divergent mores and expectations in countries where it is frequently practiced.⁸⁹ Such a defense cannot overcome the fact that, as a rule, FGM/C may be physically and emotionally damaging, seriously affecting a girl's reproductive, sexual, and mental health. It is intrinsically a violation of the girl's human rights, compromising her bodily integrity without any medical benefit, without her consent (or, frequently, even her assent). It represents an extreme case of sex discrimination through attempting to control a woman's sexuality.³ For these reasons, the practice is condemned by a vast number of health care organizations.^{3,90,91}

While condemning the practice itself, as discussed previously, it is important to show cultural sensitivity to those who practiced FGM/C in their home countries. Some parents may not have felt they had a choice, given prevailing cultural expectations, believing that FGM/C gave their daughters the best chance of succeeding in a society where it was a prerequisite for marriage and acceptance.⁹² Other parents might not have been fully aware of what was going to happen to their children or believed it had some medical benefit. Thus, the fact that a girl underwent this procedure is not a sign that her parents do not care about her or that they are more likely to engage in other forms of abuse.

So, although it is important to take active steps to prevent children from subsequently being subjected to FGM/C, it is also important to treat families whose children have already undergone FGM/C with compassion. Experience suggests that building rapport with parents increases the probability that they will give permission for remedial interventions. Such an approach may

also help persuade the family to forgo FGM/C with their other children and perhaps enable advocacy efforts with their local community as well as extended family in their country of origin.

FGM/C performed by health care providers is not uncommon, representing 18% of cases from all countries with available data. In some countries, health care providers are responsible for three-quarters of FGM/C procedures.⁹³ If asked to perform the procedure, even health care professionals who are morally opposed to FGM/C might agree to do so out of a sense of cultural respect or because they believe the alternative (ie, the family seeking the procedure from traditional practitioners) to be even worse.

By agreeing to perform the procedure, however, health care providers are granting it medical legitimacy, which not only undercuts the moral prohibition on the procedure but also contributes to its spread and ongoing societal acceptance. As the WHO notes, "It can also lead some health-care providers to develop a professional and financial interest in upholding the practice,"¹⁵ and although the immediate risks could be reduced if the procedure were performed by a trained professional, the risks of the previously noted long-term complications remain.

THE LAW AND FGM/C IN MINORS IN THE UNITED STATES

Within the United States, there are several legal issues that confront health care providers in the context of a suspected FGM/C case, including the following:

1. applicable federal and state laws;
2. consent and assent;
3. reporting child protection and/or criminal activity concerns;
4. confidentiality; and
5. documentation.

Outside the United States, many countries have laws in place that criminalize the practice of FGM/C (see Table 2).

Applicable US Federal and State Laws

The Federal Prohibition of Female Genital Mutilation Act of 1996 made it illegal to perform FGM/C in the United States on children and teenagers younger than 18 years. The act criminalizes circumcising, excising, or infibulating "the whole or any part of the labia majora or labia minora or clitoris of another person who has not attained the age of 18 years," unless deemed medically necessary, and recognizes no religious or cultural exemption for the practice of any type of FGM/C. However, a recent federal district court decision, *United States v Nagarwala*,^{21,94} has found the statute unconstitutional. Despite this federal court decision invalidating the federal statute, at the time of this writing, 35 states have also enacted specific state criminal statutes against FGM/C^{95,96} (see Table 8).

Although FGM/C performed in another country before US immigration is not reportable or prosecutable, transporting a child out of the United States for the purpose of FGM/C (so-called vacation cutting) was criminalized in the Transport for Female Genital Mutilation Act of 2013. When a child is at risk for FGM/C, including when traveling to a country where FGM/C prevalence is high and in cases in which the girl's mother and/or sisters have already had FGM/C performed before US immigration, it is recommended that health care providers have an open and supportive conversation with the parents regarding the significant medical complications of FGM/C (see Complications and Management) and legal implications to parents or other caregivers if they have FGM/C performed on their child.

TABLE 8 FGM/C Laws, by State (as of July 12, 2019)

State	Applicable Law	Only Applies to Minors (<18 Unless Otherwise Specified)	Vacation Cutting Provision (Bans Travel Outside State for FGM/C)	Duty To Report (Including FGM as Child Abuse)	Cultural and Ritual Reasons and/or Consent Not a Defense	Parent or Guardian and Circumiser Subject to Prosecution	Sentence
Arkansas	A.C.A. 5-14-135, 12-18-103, 16-118-116, 17-80-121, 20-82-101, 20-82-102	X	X	X	X	X	Imprisonment 3–10 y
Arizona	A.R.S. §§ 12-513, 13-705, 13-1214, 13-3620,	X	X	X	—	—	Imprisonment 5.25–35 y and fine up to \$25 000
California ^a	Cal. Pen. Code § 273a, 273.4	X	—	—	—	X	Imprisonment 1–6 y
Colorado ^b	Col. Rev. Stat. § 18-6-401	<16	—	—	X	X	Imprisonment minimum 4 y
Delaware	Del. Code Tit. 11, § 780	X	—	—	X	X	Imprisonment up to 5 y
Florida	Fla. Stat. § 794.08	X	X	—	X	X	Imprisonment up to 15 y and/or fine up to \$10 000
Georgia ^c	O.C.G.A. § 16-5-27	X	X	—	X	X	Imprisonment 5–20 y
Idaho	I.C. 18-1506B, I.C. 19-402	X	—	—	X	—	Imprisonment up to life
Illinois	720 Ill. Comp. Stat. 5/12-34; 325 Ill. Comp. Stat. 5/3, 5/4	—	—	X	X	X	Imprisonment 6–30 y
Iowa	I.C.A. 708.16	X	X	X	X	—	Imprisonment for up to 5 y and fine of \$750–\$7500
Kansas	K.S.A. § 21-5431	X	X	—	X	X	Imprisonment 89–100 mo
Louisiana	La. R.S. 14-43.4	X	X	—	X	X	Imprisonment up to 15 y
Maryland	Md. Code Health-Gen. § 20-601, 602	X	—	—	X	X	Imprisonment up to 5 y and/or fine up to \$5000
Michigan	1931 PA 328 § 136 1978 PA 368 § 9159	X	X	—	X	X	Imprisonment up to 15 y
Minnesota	Minn. Stat. § 144.3872, 609.2245	—	—	—	X	—	Imprisonment up to 5 y and/or fine to \$10 000
Missouri	Mo. Rev. Stat. § 568.065	Under 17	—	—	X	X	Imprisonment 5–15 y
Nevada	Nev. Rev. Stat. § 200.5083	X	X	—	X	X	Imprisonment 2–10 y and/or fine up to \$10 000
New Hampshire	N.H. Rev State. § 632-A:10-d	X	—	X	X	—	Imprisonment up to 7 y
New Jersey	N.J. Stat. § 2C:24-10	X	X	—	X	X	Imprisonment 3–5 y
New York	N.Y. Penal Law § 130.85; N.Y. Public Health Law § 207(k)	X	—	—	X	X	Imprisonment up to 4 y
North Dakota	N.D. Cent. Code § 12.1-36-01	X	—	—	X	—	Imprisonment up to 5 y and/or fine up to \$10 000
Ohio	OH ST §§ 2903.32, 2929.14, 2929. 18	X	—	X	X	—	Imprisonment 2–8 y, fine up to \$40 000, and/or a fine up to \$15 000 and an additional fine up to \$25 000
Oklahoma	21 Okl. St. § 760	—	—	—	X	—	Imprisonment 3 y to life and/or fine up to \$20 000
Oregon	Or. Rev. Stat. § 163.207	X	—	—	X	X	Imprisonment up to 10 y
Pennsylvania	18 Pa. C.S.A. 3132	X	X	X	X	X	Imprisonment for > 10 y
Rhode Island ^d	R.I. Gen. Laws § 11-5-2	—	—	—	—	—	Imprisonment up to 20 y

TABLE 8 Continued

State	Applicable Law	Only Applies to Minors (<18 Unless Otherwise Specified)	Vacation Cutting Provision (Bans Travel Outside State for FGM/C)	Duty To Report (Including FGM as Child Abuse)	Cultural and Ritual Reasons and/or Consent Not a Defense	Parent or Guardian and Circumiser Subject to Prosecution	Sentence
South Carolina	Code 16-3-2210-2240	X	X	X	X	X	Imprisonment up to 20 y and/or fine up to \$20 000
South Dakota	S.D.C.L. §§ 22-18-37, 22-18-38, 22-18-39	X	X	—	X	X	Imprisonment up to 10 y and fine up to \$20 000
Tennessee	Tenn. Code § 39-13-110, 38-1-101	—	—	X	X	—	Imprisonment 2–12 y and/or fine up to \$5000
Texas	Tex. Health & Safety Code § 167.001	X	X	—	X	X	Imprisonment 6 mo to 2 y and/or fine up to \$10 000
Utah	U.C.A. 1953 76-5-701, 76-5-702, 76-5-703, 76-5-704	X	X	X	X	X	Imprisonment up to 5 y and/or fine up to \$5000
Virginia	Va. Code §§ 8.01-42.5, 18.2-51.7	X	X	—	—	X	Imprisonment up to life and/or fine up to \$100 000
West Virginia	W. Va. Code § 61-8D-3A	X	—	—	X	X	Imprisonment 2–10 years and fine \$1000–5000
Wisconsin	Wis. Stat. § 146.35	X	—	—	X	—	Imprisonment 6 y and/or fine up to \$10 000

States with no existing FGM/C laws (as of July 12, 2019): Alabama, Alaska, Connecticut, Hawaii, Indiana, Kentucky, Maine, Massachusetts, Mississippi, Montana, Nebraska, New Mexico, North Carolina, North Dakota, Oregon, Rhode Island, South Carolina, South Dakota, Tennessee, Texas, Utah, Vermont, Washington, and Wyoming. Adapted from Equality Now. Female genital mutilation in the United States. Available at: <https://www.equalitynow.org/factsheets>. Accessed May 25, 2018 and from Mishori R, Warren N, Reingold R. Female genital mutilation or cutting. *Am Fam Physician*. 2018; 97(1):52A. X, existing law; —, no current legislation addressing this issue.

^a California: enhanced penalty for FGM/C under "Abandonment and Neglect of Children" (Penal Code).

^b Colorado: within child abuse law and one of few states where doctor-patient and husband-wife privileges are inapplicable in prosecutions for FGM/C.

^c Georgia: one of few states where husband-wife and other statutory privileges are inapplicable in prosecutions for FGM.

^d Rhode Island: within assault statute.

Consent and Assent

Before discussing consent and assent issues as they pertain to FGM/C, it is appropriate to review these concepts. Informed consent is the legal authorization to provide medical care to an individual. Minor children generally lack sufficient decision-making capacity to provide true informed consent, with three notable exceptions. The first involves the so-called "minor treatment statutes,"⁹⁷ which vary by state but generally permit minors to consent to treatment of sexually transmitted infections, mental illness, substance abuse, or matters related to reproductive health (including contraception, abortion, prenatal care, and pregnancy). If treatment qualifies under a state's minor treatment statute, a minor may consent to that specific treatment but not to others that fall outside the scope of the statute. Evaluation for FGM/C and treatment of its complications could impact reproductive health and, thus, may fall under the minor treatment statute of some states.

The second exception involves a minor patient who is legally emancipated. Emancipation⁹⁸ may be automatically conferred by taking a specific action, which varies by state, such as getting married or serving in the active duty military, or may be declared by a court after the minor fulfills specific requirements such as being self-supporting and either being enrolled in high school or having obtained one's diploma.

The third exception involves being deemed a "mature minor"⁹⁹ after being assessed for relevant factors such as reasoning ability and intellectual capacity.¹⁰⁰

Again, state laws vary as to the precise requirements for a minor to be deemed sufficiently mature to make her own health care decisions. It is recommended that health care providers not assume a minor is

mature unless provided with clear court documentation. Unlike the minor treatment statutes, emancipated and mature minors are granted the right to make all their own medical decisions, which would include not only evaluation of FGM/C but also interventions to treat it and its complications.

Outside these specific exceptions, parents are tasked with making nonemergency medical decisions for their minor children, which is termed “parental permission.” But even if a child is incapable of informed consent, she still has a role in medical decision-making. It is recognized that a child’s decisional capacity evolves over time, and so “assent” refers to a pediatric patient’s agreement to evaluation and treatment to the degree that she is able to comprehend what is being proposed. This involves developmentally appropriate awareness of the nature of the condition, appreciation of what to expect with tests or treatments, and being free of inappropriate pressure.¹⁰¹ In nonemergency situations, the older child and adolescent should give assent to evaluation and/or treatment.

There are two other situations in which parental permission is not required for the evaluation and treatment of a child. The first is when abuse is suspected, such as FGM/C that occurred in the United States, or as vacation cutting after immigration to the United States. Most states grant immunity to a provider who assists or participates in an investigation of allegation of maltreatment (ie, conducts a nonemergency evaluation for abuse, including the physical examination, and taking necessary photographs or radiographs and performing medically relevant tests) from any civil or criminal liability related to that participation.¹⁰² It is prudent for health care professionals to be knowledgeable of their state-specific child maltreatment legislation (see Table 8). If questions arise, it

may be wise to consult with a child abuse pediatrician.

Even if parental permission is not required for the reasons noted here, if the patient is old enough to provide assent, it is advisable to obtain this before proceeding. Additionally, maintaining open lines of communication with the patient’s parents is helpful, which may include informing them of what is being performed and why.

The other context in which parental permission is not required is emergent situations such as active hemorrhage or imminent delivery with infibulation. If the parents are unavailable to provide permission, consent may be presumed if three conditions hold:

1. there is a serious and immediate threat to life or health;
2. there is a need for urgent intervention (delay in care is not safe); and
3. the health care provider administers only care and treatment of emergency conditions that pose an immediate threat to the child.¹⁰³

In such situations in which the parents are available yet withhold permission, evaluation and treatment may proceed on the basis of the presumption of medical neglect and the duty of the state to protect the patient from harm (the doctrine of *parens patriae*).

Reporting Child Abuse

Health care providers in the United States are mandated reporters of suspected child maltreatment, which includes FGM/C that occurred in the United States or as vacation cutting outside the United States after this practice was criminalized in 2013. Physical examination findings suggestive of FGM/C, with previous documentation of normal genitalia, should prompt reporting to CPS.

FGM/C that occurred before immigration to the United States does not meet the legal requirement for breaching confidentiality by reporting to state agencies. Furthermore, reporting past or current FGM/C runs the risk of damaging not only the therapeutic relationship with an individual patient and her family but also with the immigrant community to which that family may belong. If health care providers are perceived not only as judgmental (ie, culturally insensitive) but also as agents of the state, families may be less likely to seek out needed medical care for their children. The opportunity for advocacy to prevent future potential instances of FGM/C may also be lost.

Most states also require a report to be made if there exists reasonable cause to believe that child abuse may occur in the future. Immediate or imminent risk warrants notification of local law enforcement authorities as well. If a child experienced FGM/C before immigration to the United States, which is not reportable, health care providers might, in some cases, be concerned for other female children in the home who might subsequently be subjected to FGM/C. It is important that these situations be evaluated individually and on the basis of a culturally sensitive discussion with the child’s primary care givers and child, if developmentally appropriate. It is advisable that the dialogue include a review of health risks and complications as well as legal repercussions of FGM/C. As needed, it is important that cultural concerns be addressed and that community organizations be engaged to enhance parental understanding. This dialogue should be recorded in the child’s medical record.

After such education and dialogue, if a health care provider has reasonable cause to believe that a child may subsequently be subjected to FGM/C, CPS should be notified. As mentioned previously, what constitutes

reasonable cause to believe is a nuanced and case-specific question. However, it is advised that health care providers remember that the threshold for reporting maltreatment does not require incontrovertible certainty, just a reasonable suspicion. Studies have revealed that pediatricians have multiple reasons for either delaying or not reporting suspected maltreatment (ie, mistrust of the child welfare investigative system and familiarity with the family, to name a few) and that physicians sometimes require inordinately high degrees of certainty before reporting suspected maltreatment.¹⁰⁴

If a clinician is uncertain whether the fact pattern of a particular case reaches the threshold of reasonable cause to believe, it is appropriate to consult a child abuse pediatrician. Expressed intention to engage in FGM/C, either in the United States or abroad, should prompt a report to CPS if the child's parent or caregiver cannot be dissuaded.

To avoid stereotyping, as well as harm to the therapeutic relationship, it is important to avoid making assumptions and to be attentive to implicit biases. Many families who originate from countries with high prevalence of FGM/C may travel back to the country of origin for many reasons wholly unrelated to FGM/C. Although some communities accept FGM/C as a sign of cultural identity or enhancing marriageability, anecdotal expert experience suggests that many mothers from high-prevalence countries do not want to subject their daughters to FGM/C. This may be particularly true when the mother herself has suffered medical complications, although this situation has not been systematically studied. Recognizing this, it is appropriate to engage in an open and supportive discussion with the family about their beliefs about FGM/C. This may involve inquiring as to the family's plans for their daughter (see

Appendix). Laws and regulations regarding child abuse reporting are different in other countries. It is prudent for health care providers to be cognizant of their country-specific requirements.

Confidentiality

In the adolescent patient with past, current, or future FGM/C concerns, it is important for health care providers to have a comprehensive discussion with the patient about the expectations and limitations of confidentiality. FGM/C that occurred in the United States or as vacation cutting after it was criminalized in 2013 is subject to federal and state reporting laws.

Documentation

Objective and thorough documentation is extremely important in potential (and actual) child maltreatment circumstances. The following recommendations (Do's and Don't's) may assist health care providers in ensuring appropriate clinical documentation in the FGM/C scenario.

Do's

1. Document in the medical record the particulars regarding informed consent or permission (ie, who gave it, when it was given, for what purpose, etc).
2. For children able to assent, obtain their assent before proceeding with examination of external genitalia.
3. Carefully and objectively document any examination limitations or mishaps in the record.
4. Describe physical findings in detail. When possible, and after attaining appropriate consent, photo-document abnormal genital findings and maintain them in a secure fashion in compliance with privacy rules of the Health Insurance Portability and Accountability Act. Given that

external genital examination and, particularly, photography of a girl or teenager may be difficult to explain to families from other cultures, photographs may be reserved for those times when there are concerns that suspected FGM/C constitutes child abuse.

5. Report impressions objectively, comprehensively, and in as simple language as possible. When applicable, report alternative diagnoses considered relevant to the findings and impression, such as labial adhesions or normal anatomic variants. In cases in which either identification of the diagnosis of FGM/C is not clear, it is strongly recommended to consult a health care provider who is well versed in diagnosis of FGM/C in prepubertal or pubertal girls, depending on the case, given that type I and II FGM/C may be difficult to diagnose (see Table 4). Such consultation is highly recommended before reporting to CPS, especially if the family is amenable.
6. If FGM/C has been recently performed in the United States, or abroad and after initial immigration, create the CPS report in a timely fashion, and as soon after evaluation as possible.
7. Document (in reasonable detail), where appropriate, all consultations with colleagues, patients and/or parents, and multidisciplinary partners.

Don't's

1. Insert language into the record or a report that is inflammatory, superfluous, or highly subjective (ie, "profoundly," "faulty," "sloppy," "terrible," "negligent," "careless," "horrible," "uncaring," "pathetic," "horrific," "barbaric," etc).
2. State conclusions that are not supported by specific facts or by the medical literature, especially if

the identification or diagnosis of FGM/C is unclear or uncertain.

3. Record information in the record or a report that has primarily legal implications and minimal or no patient care value.

Legal Right to Asylum Protection in the United States and FGM/C

FGM/C presents one other legal consideration for clinicians, that of US asylum protection. US asylum protection may be granted to someone who has left their native country because of persecution or fear that they will suffer from persecution,¹⁰⁵ including because of membership in a particular social group, in this case being female and living in a country where FGM/C is practiced. To be granted asylum, a person must either be physically present in the United States or at a port of entry to the United States, and certain other conditions must be met through a formal process with US Citizenship and Immigration Services.

The 1996 US ruling, the *Matter of Kasinga*, established the right of asylum protection for women and children potentially facing FGM/C.¹⁰⁶ However, the scenarios of past FGM/C and parents seeking asylum on the basis that their daughters would be subjected to FGM/C if they returned to their home country are more nuanced and case specific. It is prudent for clinicians to recognize this potential protection for their patients and to direct families to an immigration law attorney if such issues arise.

CONCLUSIONS

FGM/C in children is a complex issue with potential medical, mental health, and legal ramifications. It has no clinical benefits and is associated with significant morbidity and mortality. Health care providers caring for diverse patient populations may identify FGM/C in their patients;

however, FGM/C will only be identified if primary care providers become adept at performing external genital examinations on all children at every health supervision appointment. It is recommended that health care providers who are not comfortable with making an FGM/C diagnosis or discussing treatment options consult a specialist who is trained in addressing pediatric FGM/C. Open and culturally sensitive discussions among health care providers, parents, and children regarding FGM/C is of utmost importance in addressing FGM/C that has already occurred as well as in preventing future FGM/C from occurring.

RECOMMENDATIONS

1. Health care providers should not perform any type of FGM/C on female infants, girls, or teenagers.
2. Health care providers caring for girls at risk for FGM/C should actively counsel families against performing FGM/C, including when families travel to countries where FGM/C is practiced.
3. With consent and/or assent of the guardian and/or child documented in the patient's chart, all children should have external genitalia examined at all health supervision examinations, including the identification of the prepuce, clitoris, and labia minora and majora.
4. For children with risk factors for FGM/C, it is recommended that clinical assessment of FGM/C status be integrated into routine pediatric care and that a history of FGM/C before US immigration be documented in the health record.
5. It is recommended that health care providers who are not comfortable with making an FGM/C diagnosis or discussing treatment options consult a specialist who is trained in

addressing pediatric FGM/C (see Table 4).

6. If genital examination findings are equivocal for the presence of FGM/C and risk factors for FGM/C are present, a specialist trained in identification of FGM/C should be consulted (see Table 4).
7. The management of FGM/C should include complete documentation of clinical findings and the use of ICD-10 coding.
8. Health care providers should recommend defibulation for all girls and teenagers with type III FGM/C, particularly when complications are currently present.
9. In all cases in which defibulation is recommended, an experienced pediatric gynecologist (for young children), gynecologist (for older children and teenagers), urologist, or urogynecologist should be identified to perform the procedure.
10. Standardized training related to the identification, treatment, management, and culturally appropriate communication approaches needs to be developed and provided to health care providers who care for FGM/C-affected communities.
11. If FGM/C is suspected to have occurred in the United States, or as vacation cutting after immigration to the United States, the child should be evaluated for potential abuse. Expressed intention to engage in FGM/C, either in the United States or abroad, should also prompt a report to CPS if the child's parent or caregiver cannot be dissuaded.

ACKNOWLEDGMENT

We acknowledge the contribution of Zeinab Eyega (founder and executive director, Sauti Yetu Center for African

Women and Families) for her expert analysis of the case examples presented in the Appendix.

APPENDIX: CASE EXAMPLES AND EXPERT ANALYSIS

An example of an approach when discussing FGM/C with the child or teenager's mother may include statements such as the following:

I am learning about cultural practices in your country and understand that female genital cutting is done in your country. Were you cut as a child? Were your daughters cut while you were still living there? The reason I ask is that I am a physician and female genital cutting may have severe medical complications, including recurrent urinary tract infections, painful menstruation, and severe scarring blocking the flow of urine and menstrual blood. I want to make sure that you and your daughters are not having these issues because they can be treated. I also want to make sure that you understand that it is illegal to have a girl cut once she is living in the United States. This includes not sending her to another country to have her cut once she has been living in the United States.

Consider discussing FGM/C with the mother at the end of the visit after obtaining a history and performing the physical examination. Introducing a conversation regarding FGM/C early in a visit may serve as a barrier to establishing trust and rapport.

CASE 1

The patient is a 16-year-old teenaged refugee born in Mali and living in Mauritania before US arrival. She has established care with her primary care pediatrician, who explains that she needs to perform a full physical examination, including examination of her external genitalia. The teenager assents to the examination and is found to have type IIb FGM/C. The girl does not know that she has been cut and has no recollection of the procedure having occurred. She is confused and does not understand what her FGM/C means for her and how she will discuss this with her parents and boyfriend.

J.Y., General Pediatrician

Some girls do not recall undergoing FGM/C, particularly if it occurred at a young age. Expert opinion suggests that some parents do not inform their daughters of having been cut. In this case, it is important to explain physical findings to the patient and use diagrams, such as the one in Fig 4. She will need to be supported in understanding why she was cut, and it is recommended that the care provider explore how and if she would like to discuss her FGM/C with her mother, either with the medical provider present or not. If the patient is contemplating a sexual relationship, she may be concerned about her genitalia appearing different. She may also have questions about sexual function. These questions may be addressed either at this visit or at follow-up visits over time. Referral for culturally appropriate mental health supports may also be warranted in this case. If this patient has female siblings, it is recommended that they also have head-to-toe physical examinations, including external genitalia, and physical findings should be documented. It is recommended that a culturally sensitive discussion occur with the mother and father regarding the medical issues associated with FGM/C and that FGM/C performed in the United States or as vacation cutting is illegal. These discussions should be documented in the patient's chart, and the diagnosis of FGM/C should be included in the patient's past medical history as having occurred before arrival in the United States.

Zeinab Eyega, Founder and Executive Director, Sauti Yetu Center for African Women and Families

The pediatrician should ask how the patient feels about her diagnosis of FGM/C, if the teenager has questions about the practice, and if she has ever heard about FGM/C at school or through friends or family and if so,

what she learned and thought. It is essential to determine the teenager's support network, whether peers, a teacher, or a counselor, that can provide regular guidance and help as needed. The teenager's boyfriend may be from within or outside of her cultural group. Over time, it is important to discuss with the teenager whether she is concerned about her appearance because of her FGM/C. If she does not have any current health issues or concerns and there are no medical problems, the discussion may be left and revisited if concerns arise.

S.K.N., Child Abuse and Legal Expert

An honest but respectful discussion needs to occur, exploring the family's current beliefs regarding FGM/C, education about medical complications and/or risks, and education about US laws prohibiting the practice. It is important to remember to obtain more history about when the family came to the United States and whether there are other female siblings who may be at risk. A private discussion with the mother is recommended to learn of when and where the FGM/C occurred. If it occurred outside US jurisdiction, FGM/C is not grounds for reporting, but the safety of other younger female siblings in the house at future risk should be considered.

R.C.M., Medical Ethics Expert

The important ethical issues (including the patient's right to understand her condition and the obligation to protect female siblings who might be at risk) are well addressed in the preceding commentaries.

CASE 2

The patient is a 17-year-old Sudanese girl with type III FGM/C performed before US immigration who has severe dysmenorrhea from partial obstruction of menstrual flow. She wants to undergo defibulation. The

teenager gives permission for the pediatrician to discuss the issue with her parents and the medical recommendation to undergo defibulation because of medical complications. The parents are very concerned about defibulation and reluctant to give permission.

J.Y., General Pediatrician

With the teenager's consent, it is recommended to arrange a meeting with the parents to discuss the complications their daughter is having from her FGM/C, including severe pain with menstruation from partial obstruction of menstrual flow. Consider initiating the conversation with the parents by asking what their understanding of FGM/C is and exploring why it is or is not important to them. It is recommended to show diagrams of the teenager's anatomy and explain the issues that the infibulation is causing as well as her risk for future complications, including possible issues with scarring, chronic pain, and infertility. Several meetings may be required to review the medical issues and the recommendation to defibulate the teenager to relieve symptoms, both short- and long-term. As with case 1, if there are other female siblings in the home, it is recommended to make arrangements to perform a full physical examination on the other female siblings, including visualization of the external genitalia, and findings should be clearly documented in the chart. A frank but culturally sensitive discussion should occur with the parents, explaining medical complications and the illegality of future FGM/C documented in the chart as well as documentation of FGM/C having occurred overseas, before immigration, in the past medical history.

Zeinab Eyega, Founder and Executive Director, Sauti Yetu Center for African Women and Families

If the teenager consents to allowing a discussion with her parents, the pediatrician should facilitate

a meeting with both the teenager and parents present. It is important to learn from the parents if they have noted the medical issues, including pain, that their daughter has had because of her type III FGM/C and that the recommended treatment is defibulation. Some parents (most likely the mother) may be concerned that if their daughter is defibulated, the procedure would affect her virginity. It is important to address this concern to ensure that the teenager continues to have support from her parents after defibulation so that she does not feel isolated from her parents and other family members, both of which could negatively affect her emotional well-being. The parents may need time to process the information, and another appointment should be offered as well as the option to meet with a counselor to discuss the issue with the counselor.

S.K.N., Child Abuse and Legal Expert, and R.C.M., Medical Ethics Expert

This scenario is nuanced and could constitute medical neglect by the parents (depending on the severity of symptoms and degree of obstruction). If possible, the general pediatrician should consult a child abuse pediatrician because they will know the local CPS personnel and procedures well and may be able to provide an idea of their potential response. Furthermore, the general pediatrician should have an honest and respectful discussion with parents about the teenager's medical need for defibulation and about their failure to consent possibly requiring a report to CPS for intervention.

Although 18 years is the age of majority in nearly every state, some younger patients may possess sufficient decision-making capacity to make informed and voluntary health care decisions.¹⁰¹ If her condition represents a current threat to her health (in terms of pain, suffering, or

risk of morbidity or mortality), her parents' unwillingness to give permission to defibulation could represent medical neglect. Even if her condition is not an emergency, the patient could be declared by the court to be a mature minor, depending on the laws of her state,⁹⁹ and could thus have the legal right to consent to the procedure herself.

CASE 3

A 10-year-old girl born in the United States in 2008 to Ethiopian refugee parents presents for well-child care. She had a documented normal physical examination, with normal female genitalia, at her newborn visit. Well-child care examinations at 4, 6, and 8 years of age occurred with the genital examination marked as "deferred" at each visit. Of note, the girl traveled to Ethiopia in 2012 to visit relatives with her mom. A full physical examination, including external genitalia, reveals type Ib FGM/C. Once the child is dressed, the mother is separately asked if her child had FGM/C performed. She denies any knowledge of her child being cut abroad.

J.Y., General Pediatrician

It is important to ask the 10-year-old whether she recalls having been cut. If she does remember being cut, she will be able to provide more information regarding when and where it happened as well as who was involved. If she is unable to provide any information about the cutting, it is important to document this information in her medical chart. Although more likely the FGM/C occurred overseas on her visit with relatives, it is theoretically possible that she had FGM/C performed in the United States. In this case, it would be reasonable to consult with a child abuse specialist in your state. As with cases 1 and 2, if there are other female siblings in the house, these children should be examined, and physical findings and medical and

legal education regarding FGM/C should be clearly documented in the patient's health record.

Zeinab Eyega, Founder and Executive Director, Sauti Yetu Center for African Women and Families

The pediatrician should start by speaking with the parents separately from the child and explaining that her examination reveals FGM/C that was performed after she was born in the United States. It is important to show diagrams revealing the difference between a cut and uncut child so that the parents understand. Ask questions about other family members and if they have also had FGM/C. In some cases, biological parents may not be involved in the decision to circumcise their daughter and may not know that she was cut. In such cases, a respected elder in the community, such as a grandmother or aunt, may make this decision for the girl and have her cut.

S.K.N., Child Abuse and Legal Expert

Although this scenario may not be prosecutable as vacation cutting or reportable, as in case 1, it is advisable to gather more psychosocial history about the family makeup and the family's current beliefs about FGM/C.

R.C.M., Medical Ethics Expert

Although the patient is unable to provide informed consent for evaluation and treatment, she is developing the capacity for assent and thus is entitled to an explanation of her condition, provided in a nonjudgmental and developmentally appropriate fashion, with her questions welcomed and consistent promises of ongoing support. The pediatrician should also strive to establish rapport with the family, who may be denying knowledge because of fear of repercussions or may truly be unaware.

CASE 4

The patient is a 5-year-old female refugee from Somalia via a Kenyan refugee camp who had type IIb FGM/C performed 6 months before US immigration. The child has her urethral opening covered by labia minora, and urinary stream occurs through a 2 × 2 mm opening in the otherwise sealed labia minora. The patient has reported delay in bladder emptying and pain, per maternal report. She has no report of past urinary tract infections, prolonged fever, or vomiting.

J.Y., General Pediatrician

A supportive discussion should occur with the parents regarding the pain and medical complications associated with the child's type III FGM/C, including risk for recurrent urinary tract infections and renal scarring. Diagrams should be used to demonstrate the issues associated with acute urinary obstruction. This discussion may take several visits, with strict return precautions reviewed each time, including the need to bring the child immediately for medical evaluation if the following conditions are present: fever; vomiting, dysuria, or urgency to urinate, frequency of urination, and/or the inability to pass urine. With consent of the parents, a trusted leader in the Somali community may need to be called on to help support the parents in deciding to allow their child to undergo defibulation.

Zeinab Eyega, Founder and Executive Director, Sauti Yetu Center for African Women and Families

It is important to use diagrams to review the physical findings of female genital cutting with the parents and to explain why the child is having problems emptying her bladder and has pain. Explain that it is recommended to have the child defibulated and that this will not affect her virginity or her ability in the United States to marry later in life. If there are other daughters, they should also be examined.

S.K.N., Child Abuse and Legal Expert

A thorough psychosocial history should be obtained to assess the social dynamics of the family. An honest and respectful discussion should occur that, as in case 2, should highlight the possible need to report to CPS if permission is denied for the health and safety of the child. Again, if available, consultation with a child abuse pediatrician is advised because that individual will know the local CPS personnel, procedures, and responses well.

R.C.M., Medical Ethics Expert

The patient has a condition that leads to pain and impaired urinary outflow. Irrespective of the cause, this needs to be addressed. The clinical situation should be explained to the parents as well as recommendations made to treat the urinary retention and pain. Parental refusal of the intervention to address these problems suggests they are not acting in the best interest of the child.

LEAD AUTHORS

Janine Young, MD, FAAP
Nawal M. Nour, MD, MPH, FACOG
Robert C. Macauley, MD, FAAP
Sandeep K. Narang, MD, JD, FAAP

CONTRIBUTING AUTHOR

Crista Johnson-Agbakwu, MD, MSc, FACOG

SECTION ON GLOBAL HEALTH EXECUTIVE COMMITTEE, 2019–2020

Patrick T. McGann, MD, MS, FAAP, Chairperson
Chiquita Palha De Sousa, MD, MPH, FAAP
Heather Haq, MD, MHS, FAAP
Alcy R. Torres, MD, FAAP
Ifelayo P. Ojo, MBBS, MPH, FAAP
Nicole E. St. Clair, MD, FAAP
Parminder Suchdev, MD, MPH, FAAP, Immediate Past Chairperson

FORMER MEMBERS OF THE SECTION

Linda D. Arnold, MD, FAAP
Kevin J. Chan, MD, MPH, FAAP
Cynthia R. Howard, MD, MPH, FAAP
Katherine Yun, MD, MHS, FAAP

COMMITTEE ON BIOETHICS, 2019–2020

Robert Conover Macauley, MD, MDiv, FAAP, Chairperson
Ratna Basak, MD, FAAP

Gina Marie Geis, MD, FAAP
Naomi Tricot Laventhal, MD, FAAP, Section
Member – *Section on Bioethics*
Douglas John Opel, MD, MPH, FAAP
Mindy B. Statter, MD, FAAP

COMMITTEE ON MEDICAL LIABILITY AND RISK MANAGEMENT, 2019–2020

Jonathan M. Fanaroff, MD, JD, FAAP,
Chairperson
Robin L. Altman, MD, FAAP
Steven A. Bondi, JD, MD, FAAP
Sandeep K. Narang, MD, JD, FAAP
Richard L. Oken, MD, FAAP
John W. Rusher, MD, JD, FAAP
Karen A. Santucci, MD, FAAP
James P. Scibilia, MD, FAAP
Susan M. Scott, MD, JD, FAAP
Laura J. Sigman, MD, JD, FAAP
Willa Michelle Terry, MD, FAAP
Robert Turbow, MD, JD, FAAP

FORMER MEMBERS OF THE COMMITTEE

Robin L. Altman, MD, FAAP
Sandeep K. Narang, MD, JD, FAAP

James P. Scibilia, MD, FAAP

LIAISONS

Mary Lynn Dell, MD, DMin, Committee on
Bioethics Liaison – *American Academy of
Child and Adolescent*
Douglas Scott Diekema, MD, MPH, FAAP,
Committee on Bioethics Liaison – *American
Board of Pediatrics*
David Shalowitz, MD, Committee on
Bioethics Liaison – *American College of
Obstetricians and Gynecologists*

TECHNICAL CONSULTANT

Jasmine Abdulcadir, MD, FMH

LEGAL CONSULTANT

Nanette Elster, JD, MPH, Committee on
Bioethics Legal Consultant

STAFF

Terrell Carter, MHS
Sherri L. Smith, MPH
Julie Kersten Ake

Florence Rivera, MPH
Erick Amick, MPH, MA

ACKNOWLEDGMENTS

The authors acknowledge the
contribution of Zeinab Eyega,
Founder and Executive Director, Sauti
Yetu, Center for African Women and
Families, for her expert analysis of the
case examples presented in the
Appendix.

ABBREVIATIONS

CPS: child protective services
FGM/C: female genital mutilation
or cutting
ICD-10: *International Classification
of Diseases, 10th Revision*
WHO: World Health Organization

This document is copyrighted and is property of the American Academy of Pediatrics and its Board of Directors. All authors have filed conflict of interest statements with the American Academy of Pediatrics. Any conflicts have been resolved through a process approved by the Board of Directors. The American Academy of Pediatrics has neither solicited nor accepted any commercial involvement in the development of the content of this publication.

DOI: <https://doi.org/10.1542/peds.2020-1012>

Address correspondence to Janine Young, MD, FAAP. E-mail: janine.young@dhha.org

PEDIATRICS (ISSN Numbers: Print, 0031-4005; Online, 1098-4275).

Copyright © 2020 by the American Academy of Pediatrics

FINANCIAL DISCLOSURE: Dr Johnson-Agbakwu has a grant relationship with Arizona State University from the 2018 copyright of “Female Genital Mutilation/Cutting (FGM/C): A Visual Reference and Learning Tool for Health Care Professionals.”

FUNDING: No external funding.

POTENTIAL CONFLICT OF INTEREST: Dr Johnson-Agbakwu has a grant relationship with Arizona State University from the 2018 copyright of “Female Genital Mutilation/Cutting (FGM/C): A Visual Reference and Learning Tool for Health Care Professionals.”

REFERENCES

1. Committee on the Elimination of Discrimination against Women. *Convention on the Elimination of All Forms of Discrimination Against Women: General Recommendation No. 14: Female Circumcision*. New York, NY: United Nations; 1990
2. World Health Organization. *Eliminating Female Genital Mutilation: An Interagency Statement: OHCHR, UNAIDS, UNDP, UNECA, UNESCO, UNFPA, UNHCR, UNIFEM, WHO*. Geneva, Switzerland: World Health Organization; 2008
3. FIGO Committee for the Study of Ethical Aspects of Human Reproduction and Women's Health. *Ethical Issues in Obstetrics and Gynecology*. London, United Kingdom: International Federation of Gynecology and Obstetrics; 2012
4. Council on Scientific Affairs, American Medical Association. Female genital mutilation. *JAMA*. 1995;274(21): 1714–1716
5. United Nations Population Fund. Female genital mutilation. Available at: <https://www.unfpa.org/female-genital-mutilation>. Accessed May 24, 2018
6. World Health Organization. Female genital mutilation. 2018. Available at: <https://www.who.int/news-room/fact-sheets/detail/female-genital-mutilation>. Accessed May 24, 2018
7. Kopelman LM. Female circumcision/genital mutilation and ethical relativism. *Second Opin*. 1994;20(2): 55–71
8. World Health Organization. Female genital mutilation (FGM). 2013. Available at: www.who.int/reproductivehealth/topics/fgm/prevalence/en/. Accessed May 24, 2018

9. Zurynski Y, Sureshkumar P, Phu A, Elliott E. Female genital mutilation and cutting: a systematic literature review of health professionals' knowledge, attitudes and clinical practice. *BMC Int Health Hum Rights*. 2015;15:32
10. Creighton SM, Hodes D. Female genital mutilation: what every paediatrician should know. *Arch Dis Child*. 2016; 101(3):267–271
11. United Nations Children's Fund. Female genital mutilation (FGM). Available at: <https://data.unicef.org/topic/child-protection/female-genital-mutilation/>. Accessed May 12, 2019
12. United Nations Entity for Gender Equality and the Empowerment of Women. *Female Genital Mutilation/Cutting and Violence Against Women and Girls: Strengthening the Policy Linkages Between Different Forms of Violence*. New York, NY: United Nations Entity for Gender Equality and the Empowerment of Women; 2017
13. Goldberg H, Stupp P, Okoroh E, Besera G, Goodman D, Danel I. Female genital mutilation/cutting in the United States: updated estimates of women and girls at risk, 2012. *Public Health Rep*. 2016; 131(2):340–347
14. United Nations Children's Fund. Female genital mutilation/cutting: a global concern. Available at: https://www.unicef.org/media/files/FGMC_2016_brochure_final_UNICEF_SPREAD.pdf. Accessed May 24, 2018
15. World Health Organization. An Update on WHO's Work on Female Genital Mutilation (FGM): Progress Report. Geneva, Switzerland: World Health Organization; 2011. Available at: https://www.who.int/reproductivehealth/publications/fgm/rhr_11_18/en/. Accessed April 29, 2020
16. United Nations Children's Fund. *Female Genital Mutilation/Cutting: A Statistical Overview and Exploration of the Dynamics of Change*. New York, NY: United Nations Children's Fund; 2013
17. BBC News. Russia furore over FGM in mainly Muslim Dagestan. BBC News. August 18, 2016. Available at: <https://www.bbc.com/news/world-europe-37115746>. Accessed April 29, 2020
18. Ross CT, Campiño PJ, Winterhalter B. Frequency-dependent social transmission and the interethnic transfer of female genital modification in the African diaspora and indigenous populations of Colombia. *Hum Nat*. 2015;26(4):351–377
19. Victor D. Father imprisoned for genital cutting is deported to Ethiopia. *The New York Times*. March 14, 2017. Available at: <https://www.nytimes.com/2017/03/14/us/father-imprisoned-for-genital-cutting-is-deported-to-ethiopia.html>. Accessed May 24, 2018
20. Burstyn L. Female circumcision comes to America. *The Atlantic*. October 1, 1995. Available at: <https://www.theatlantic.com/magazine/archive/1995/10/female-circumcision-comes-to-america/306051/>. Accessed May 24, 2018
21. Belluck P. Michigan case adds U.S. dimension to debate on genital mutilation. *The New York Times*. June 10, 2017. Available at: <https://www.nytimes.com/2017/06/10/health/genital-mutilation-muslim-dawoodi-bohra-michigan-case.html>. Accessed May 24, 2018
22. Hicks M. Judge dismisses most serious remaining charge against doctor accused of genital mutilation. *The Detroit News*. March 5, 2020. Available at: <https://www.detroitnews.com/story/news/local/michigan/2020/03/05/judge-dismisses-charge-against-doctor-female-genital-mutilation/4960323002/>. Accessed April 29, 2020
23. Semu-Banda P. For many girls, school holidays means FGM “cutting season.” 2017. Available at: <https://www.unfpa.org/cuttingseason>. Accessed May 24, 2018
24. Sanctuary for Families. *Female Genital Mutilation in the United States. Protecting Girls and Women in the U.S. From FGM and Vacation Cutting*. New York, NY: Sanctuary for Families; 2013
25. Population Reference Bureau. *Female Genital Mutilation/Cutting: Data and Trends*. Washington, DC: Population Reference Bureau; 2010
26. Tamaddon L, Johnsdotter S, Liljestrand J, Essén B. Swedish health care providers' experience and knowledge of female genital cutting. *Health Care Women Int*. 2006;27(8):709–722
27. Kaplan-Marcusan A, Torán-Monserrat P, Moreno-Navarro J, Castany Fàbregas MJ, Muñoz-Ortiz L. Perception of primary health professionals about female genital mutilation: from healthcare to intercultural competence. *BMC Health Serv Res*. 2009;9(1):11
28. Young J, Rodrigues KK, Imam B, Johnson-Agbakwu C. Female genital mutilation/cutting-pediatric physician knowledge, training, and general practice approach [published online ahead of print October 10, 2019]. *J Immigr Minor Health*. doi:10.1007/s10903-019-00938-x
29. Hess RF, Weinland J, Saalinger NM. Knowledge of female genital cutting and experience with women who are circumcised: a survey of nurse-midwives in the United States. *J Midwifery Womens Health*. 2010;55(1): 46–54
30. Lazar JN, Johnson-Agbakwu CE, Davis OI, Shipp MP. Providers' perceptions of challenges in obstetrical care for Somali women. *Obstet Gynecol Int*. 2013; 2013:149640
31. Jacoby SD, Smith A. Increasing certified nurse-midwives' confidence in managing the obstetric care of women with female genital mutilation/cutting. *J Midwifery Womens Health*. 2013;58(4): 451–456
32. Atkinson HG, Geisler A. Developing physician educational competencies for the management of female genital cutting: a call to action. *J Womens Health (Larchmt)*. 2019;28(7):997–1003
33. Creighton SM, Dear J, de Campos C, Williams L, Hodes D. Multidisciplinary approach to the management of children with female genital mutilation (FGM) or suspected FGM: service description and case series. *BMJ Open*. 2016;6(2):e010311
34. Zurynski Y, Phu A, Sureshkumar P, Cherian S, Devereil M, Elliott EJ, for Australian Paediatric Surveillance Unit Female Genital Mutilation Study Steering Committee. Female genital mutilation in children presenting to Australian paediatricians. *Arch Dis Child*. 2017;102(6):509–515
35. Sureshkumar P, Zurynski Y, Moloney S, Raman S, Varol N, Elliott EJ. Female genital mutilation: survey of paediatricians' knowledge, attitudes

- and practice. *Child Abuse Negl.* 2016;55: 1–9
36. Hagan JF, Shaw JS, Duncan PM, eds. *Bright Futures: Guidelines for Health Supervision of Infants, Children, and Adolescents*, 4th ed. Elk Grove Village, IL: American Academy of Pediatrics; 2017
 37. Committee on Practice and Ambulatory Medicine. Use of chaperones during the physical examination of the pediatric patient. *Pediatrics*. 2011;127(5):991–993
 38. Shell-Duncan B, Hernlund Y, Wander K, Moreau A. *Contingency and Change in the Practice of Female Genital Cutting: Dynamics of Decision Making in Senegambia. Summary Report*. Seattle, Washington: Department of Anthropology, University of Washington; 2010
 39. World Health Organization. International Statistical classification of diseases and Related Health Problems 10th Revision. 2016. Available at: <https://icd.who.int/browse10/2016/en>. Accessed xx xx, xxxx
 40. Population Reference Bureau. Women and girls at risk of female genital mutilation/cutting in the United States. 2016. Available at: <https://www.prb.org/us-fgmc/>. Accessed May 25, 2018
 41. Berg RC, Underland V, Odgaard-Jensen J, Fretheim A, Vist GE. Effects of female genital cutting on physical health outcomes: a systematic review and meta-analysis. *BMJ Open*. 2014;4(11): e006316
 42. Nour NM. Female genital cutting: clinical and cultural guidelines. *Obstet Gynecol Surv*. 2004;59(4):272–279
 43. Berg RC, Underland V. *Immediate health consequences of Female Genital Mutilation/Cutting (FGM/C)*. Oslo, Norway: Knowledge Centre for the Health Services at The Norwegian Institute of Public Health; 2014. Available at: www.ncbi.nlm.nih.gov/books/NBK464798/. Accessed August 30, 2019
 44. Brewer DD, Potterat JJ, Roberts JM Jr, Brody S. Male and female circumcision associated with prevalent HIV infection in virgins and adolescents in Kenya, Lesotho, and Tanzania. *Ann Epidemiol*. 2007;17(3):217–226
 45. Banks E, Meirik O, Farley T, Akande O, Bathija H, Ali M; WHO Study Group on Female Genital Mutilation and Obstetric Outcome. Female genital mutilation and obstetric outcome: WHO collaborative prospective study in six African countries. *Lancet*. 2006;367(9525): 1835–1841
 46. Rodríguez MI, Say L, Abdulkadir J, Hindin MJ. Clinical indications for cesarean delivery among women living with female genital mutilation. *Int J Gynaecol Obstet*. 2017;139(1):21–27
 47. Rodríguez MI, Seuc A, Say L, Hindin MJ. Episiotomy and obstetric outcomes among women living with type 3 female genital mutilation: a secondary analysis. *Reprod Health*. 2016;13(1):131
 48. Berg RC, Denison E, Fretheim A. *Psychological, Social and Sexual Consequences of Female Genital Mutilation/Cutting (FGM/C): A Systematic Review of Quantitative Studies*. Oslo, Norway: Knowledge Centre for the Health Services at The Norwegian Institute of Public Health; 2010
 49. Ahmed MR, Shaaban MM, Meki HK, et al. Psychological impact of female genital mutilation among adolescent Egyptian girls: a cross-sectional study. *Eur J Contracept Reprod Health Care*. 2017;22(4):280–285
 50. Knipscheer J, Vloeberghs E, van der Kwaak A, van den Muijsenbergh M. Mental health problems associated with female genital mutilation. *BJPsych Bull*. 2015;39(6):273–277
 51. Abdulkadir J, Tille JC, Petignat P. Management of painful clitoral neuroma after female genital mutilation/cutting. *Reprod Health*. 2017; 14(1):22
 52. Nour NM, Michels KB, Bryant AE. Defibulation to treat female genital cutting: effect on symptoms and sexual function. *Obstet Gynecol*. 2006;108(1): 55–60
 53. Effa E, Ojo O, Ihesie A, Meremikwu MM. Deinfibulation for treating urologic complications of type III female genital mutilation: a systematic review. *Int J Gynaecol Obstet*. 2017;136(suppl 1): 30–33
 54. Nour NM. Urinary calculus associated with female genital cutting. *Obstet Gynecol*. 2006;107(2 pt 2):521–523
 55. Rouzi AA. Epidermal clitoral inclusion cysts: not a rare complication of female genital mutilation. *Hum Reprod*. 2010; 25(7):1672–1674
 56. Victoria-Martínez AM, Cubells-Sánchez L, Martínez-Leborans L, Sánchez-Carazo JL, de Miquel VA. Vulvar epidermal inclusion cyst as a long-term complication of female genital mutilation. *Indian J Dermatol*. 2016; 61(1):119
 57. Morison L, Scherf C, Ekpo G, et al. The long-term reproductive health consequences of female genital cutting in rural Gambia: a community-based survey. *Trop Med Int Health*. 2001;6(8): 643–653
 58. Brady M. Female genital mutilation: complications and risk of HIV transmission. *AIDS Patient Care STDS*. 1999;13(12):709–716
 59. Reisel D, Creighton SM. Long term health consequences of female genital mutilation (FGM). *Maturitas*. 2015;80(1): 48–51
 60. Almroth L, Elmusharaf S, El Hadi N, et al. Primary infertility after genital mutilation in girlhood in Sudan: a case-control study. *Lancet*. 2005;366(9483): 385–391
 61. Thabet SM, Thabet AS. Defective sexuality and female circumcision: the cause and the possible management. *J Obstet Gynaecol Res*. 2003;29(1):12–19
 62. Chalmers B, Hashi KO. 432 Somali women's birth experiences in Canada after earlier female genital mutilation. *Birth*. 2000;27(4):227–234
 63. Stewart H, Morison L, White R. Determinants of coital frequency among married women in Central African Republic: the role of female genital cutting. *J Biosoc Sci*. 2002;34(4): 525–539
 64. Okonofu FE, Larsen U, Oronsaye F, Snow RC, Slangier TE. The association between female genital cutting and correlates of sexual and gynaecological morbidity in Edo State, Nigeria. *BJOG*. 2002;109(10): 1089–1096
 65. Berg RC, Taraldsen S, Said MA, Sørbye IK, Vangen S. The effectiveness of surgical interventions for women with FGM/C: a systematic review. *BJOG*. 2018; 125(3):278–287

66. Abdulcadir J, Rodríguez MI, Say L. A systematic review of the evidence on clitoral reconstruction after female genital mutilation/cutting. *Int J Gynaecol Obstet*. 2015;129(2):93–97
67. Abdulcadir J, Marras S, Catania L, Abdulcadir O, Petignat P. Defibulation: a visual reference and learning tool. *J Sex Med*. 2018;15(4):601–611
68. American College of Obstetricians and Gynecologists. *Female Genital Cutting: Clinical Management of Circumcised Women*, 2nd ed. Washington, DC: American College of Obstetricians and Gynecologists; 2008
69. Abdulcadir J, Bianchi Demicheli F, Willame A, Recordon N, Petignat P. Posttraumatic stress disorder relapse and clitoral reconstruction after female genital mutilation. *Obstet Gynecol*. 2017; 129(2):371–376
70. Pierce S, Bolter J, Selee A. *U.S. Immigration Policy Under Trump: Deep Changes and Lasting Impacts*. Washington, DC: Migration Policy Institute; 2018
71. Hacker K, Chu J, Leung C, et al. The impact of Immigration and Customs Enforcement on immigrant health: perceptions of immigrants in Everett, Massachusetts, USA. *Soc Sci Med*. 2011; 73(4):586–594
72. Redden M. Undocumented immigrants avoid vital nutrition services for fear of deportation. *The Guardian*. May 9, 2017. Available at: <https://www.theguardian.com/us-news/2017/may/09/undocumented-immigrants-wic-nutrition-services-deportation>. Accessed June 5, 2019
73. Medina J. Too scared to report sexual abuse. The fear: deportation. *The New York Times*. April 30, 2017. Available at: <https://www.nytimes.com/2017/04/30/us/immigrants-deportation-sexual-abuse.html>. Accessed June 5, 2019
74. Hoffman J. Sick and afraid, some immigrants forgo medical care. *The New York Times*. June 26, 2017. Available at: <https://www.nytimes.com/2017/06/26/health/undocumented-immigrants-health-care.html>. Accessed June 5, 2019
75. Vissandjée B, Denetto S, Migliardi P, Proctor J. Female genital cutting (FGC) and the ethics of care: community engagement and cultural sensitivity at the interface of migration experiences. *BMC Int Health Hum Rights*. 2014;14(1): 13
76. Vissandjée B, Kantiébo M, Levine A, N'Dejuru R. The cultural context of gender, identity: female genital, excision and infibulation. *Health Care Women Int*. 2003;24(2):115–124
77. Johnson-Agbakwu CE, Helm T, Killawi A, Padela AI. Perceptions of obstetrical interventions and female genital cutting: insights of men in a Somali refugee community. *Ethn Health*. 2014; 19(4):440–457
78. Baillot H, Murray N, Connelly E, Howard N. Addressing female genital mutilation in Europe: a scoping review of approaches to participation, prevention, protection, and provision of services. *Int J Equity Health*. 2018;17(1): 21
79. Varol N, Turkmani S, Black K, Hall J, Dawson A. The role of men in abandonment of female genital mutilation: a systematic review. *BMC Public Health*. 2015;15(1):1034
80. Creighton SM, Samuel Z, Otoo-Oyortey N, Hodes D. Tackling female genital mutilation in the UK. *BMJ*. 2019;364:115
81. Macfarlane A. Misleading use of FGM statistics compounds concerns about their reliability. *BMJ*. 2019;364:1927
82. Karlsen S, Mogilnicka M, Carver N, Pantazis C. Female genital mutilation: empirical evidence supports concerns about statistics and safeguarding. *BMJ*. 2019;364:1915
83. Seven days in medicine: 28 November to 4 December 2018. *BMJ*. 2018;363: k5126
84. Gangoli G, Gill A, Mulvihill N, Hester M. Perception and barriers: reporting female genital mutilation. *J Aggress Confl Peace Res*. 2018;10(4):251–260
85. Vogt S, Efferson C, Fehr E. The risk of female genital cutting in Europe: comparing immigrant attitudes toward uncut girls with attitudes in a practicing country. *SSM Popul Health*. 2017;3:283–293
86. Wahlberg A, Johnsdotter S, Ekholm Selling K, Källestål C, Essén B. Factors associated with the support of pricking (female genital cutting type IV) among Somali immigrants - a cross-sectional study in Sweden. *Reprod Health*. 2017; 14(1):92
87. Wahlberg A, Johnsdotter S, Selling KE, Källestål C, Essén B. Baseline data from a planned RCT on attitudes to female genital cutting after migration: when are interventions justified? *BMJ Open*. 2017;7(8):e017506
88. Agency for Healthcare Research and Quality. Community-driven clinic for refugee women enhances access to comprehensive, culturally sensitive care across the reproductive life span. 2014. Available at: <https://innovations.ahrq.gov/profiles/community-driven-clinic-refugee-women-enhances-access-comprehensive-culturally-sensitive>. Accessed February 1, 2018
89. Mendelsohn N. At the crossroads: the case for and against a cultural defense to female genital mutilation. *Rutgers Law Rev*. 2004;56(4):1011–1038
90. World Health Organization. Eliminating female genital mutilation. An Interagency statement. 2008. Available at: https://www.un.org/womenwatch/daw/csw/csw52/statements_missions/Interagency_Statement_on_Eliminating_FGM.pdf. Accessed April 30, 2020
91. Choudhary I, Mishori R, Kim S. Words matter: charting the landscape of US and international health profession organizations' public statements about FGM/C. *J Immigr Minor Health*. 2019; 21(4):893–904
92. Alavi R. Female genital mutilation: a capabilities approach. *Auslegung J Philos*. 2003;26(2):1–25
93. Joint United Nations Programme on HIV and AIDS; United Nations Development Programme; United Nations Population Fund. *Global Strategy to Stop Health-Care Providers From Performing Female Genital Mutilation*. Geneva, Switzerland: World Health Organization; 2010
94. United States v. Nagarwala, 350 F Supp 3d 613 (ED Mich 2018)
95. Equality Now. US laws against FGM—state by state. Available at: https://www.equalitynow.org/us_laws_against_fgm_state_by_state. Accessed April 30, 2020
96. AHA Foundation. FGM legislation by state. Available at: <https://www.aha.org>

- theahafoundation.org/female-genital-mutilation/fgm-legislation-by-state/. Accessed March 7, 2019
97. Boonstra H, Nash E. Minors and the right to consent to health care. *Issues Brief (Alan Guttmacher Inst)*. 2000;(2): 1–6
98. Cornell Law School. Emancipation of minors - laws.. 2008. Available at: https://www.law.cornell.edu/wex/table_emancipation. Accessed May 25, 2018
99. Coleman DL, Rosoff PM. The legal authority of mature minors to consent to general medical treatment. *Pediatrics*. 2013;131(4):786–793
100. Driggs AE. The mature minor doctrine: do adolescents have the right to die? *Health Matrix Clevel*. 2001;11(2): 687–717
101. Committee on Bioethics. Informed consent in decision-making in pediatric practice. *Pediatrics*. 2016;138(2): e20161484
102. Child Welfare Information Gateway. *Immunity for Reporters of Child Abuse and Neglect*. Washington, DC: US Department of Health and Human Services, Children's Bureau; 2019
103. Committee on Pediatric Emergency Medicine and Committee on Bioethics. Consent for emergency medical services for children and adolescents. *Pediatrics*. 2011;128(2):427–433
104. Levi BH, Brown G. Reasonable suspicion: a study of Pennsylvania pediatricians regarding child abuse. *Pediatrics*. 2005; 116(1) Available at: www.pediatrics.org/cgi/content/full/116/1/e5
105. US Citizenship and Immigration Services. Asylum. 2019. Available at: <https://www.uscis.gov/humanitarian/refugees-asylum/asylum>. Accessed February 4, 2018
106. US Department of Justice, Executive Office for Immigration Review, Board of Immigration Appeals. In re Fauziya Kasinga, applicant. 1996. Available at: <https://www.justice.gov/sites/default/files/eoir/legacy/2014/07/25/3278.pdf>. Accessed February 4, 2017
107. Kimenyi MS. The long road to South Sudan's secession vote. 2010. Available at: <https://www.brookings.edu/opinions/the-long-road-to-south-sudans-secession-vote/>. Accessed March 1, 2020
108. United Nations Population Fund. Analysis of legal frameworks on female genital mutilation in selected countries in West Africa. 2018. Available at: <https://wcaro.unfpa.org/sites/default/files/pub-pdf/UNFPA-ANALYSIS-ON-FGM-WEB.pdf>. Accessed January 10, 2019
109. Centers for Disease Control and Prevention. International Classification of Diseases, Tenth Revision, Clinical Modification (ICD-10-CM). 2019. Available at: <https://www.cdc.gov/nchs/icd/icd10cm.htm>. Accessed December 14, 2017
110. Abdulcadir J, Botsikas D, Bolmont M, et al. Sexual anatomy and function in women with and without genital mutilation: a cross-sectional study. *J Sex Med*. 2016;13(2):226–237
111. World Health Organization. *Care of Girls and Women Living with Female Genital Mutilation: A Clinical Handbook*. Geneva, Switzerland: World Health Organization. Available at: www.who.int/reproductivehealth/publications/health-care-girls-women-living-with-FGM/en/. Accessed May 29, 2019
112. US Government Accountability Office. Female genital mutilation/cutting: existing federal efforts to increase awareness should be improved. 2016. Available at: <https://www.gao.gov/products/GAO-16-645>. Accessed September 10, 2019
113. World Health Organization. *WHO Guidelines on the Management of Health Complications from Female Genital Mutilation*. Geneva, Switzerland: World Health Organization. Available at: www.who.int/reproductivehealth/topics/fgm/management-health-complications-fgm/en/. Accessed September 10, 2019
114. United Nations Population Fund. Female genital mutilation (FGM) frequently asked questions. Available at: <https://www.unfpa.org/resources/female-genital-mutilation-fgm-frequently-asked-questions>. Accessed April 30, 2020
115. US Citizenship and Immigration Services. Female genital mutilation or cutting (FGM/C). 2018. Available at: <https://www.uscis.gov/fgmc>. Accessed November 13, 2017
116. Centers for Disease Control and Prevention. Guidelines for the US domestic medical examination for newly arriving refugees. 2019. Available at: <https://www.cdc.gov/immigrantrefugeehealth/guidelines/domestic/domestic-guidelines.html>. Accessed September 10, 2019
117. American Academy of Pediatrics. Immigrant child health toolkit. Available at: www.aap.org/en-us/advocacy-and-policy/aap-health-initiatives/Immigrant-Child-Health-Toolkit/Pages/Clinical-Care.aspx. Accessed September 10, 2019
118. Abdulcadir J, Catania L, Hindin MJ, Say L, Petignat P, Abdulcadir O. Female genital mutilation: a visual reference and learning tool for health care professionals. *Obstet Gynecol*. 2016; 128(5):958–963
119. National Health Service. Overview: female genital mutilation (FGM). 2017. Available at: <https://www.nhs.uk/conditions/female-genital-mutilation-fgm/>. Accessed November 3, 2017
120. National Health Service, Department of Health and Social Care. Female genital mutilation (FGM): resources for healthcare staff. 2015. Available at: <https://www.gov.uk/government/collections/female-genital-mutilation-fgm-guidance-for-healthcare-staff>. Accessed August 12, 2019
121. National Health Service, Department of Health and Social Care. FGM: mandatory reporting in healthcare. 2017. Available at: <https://www.gov.uk/government/publications/fgm-mandatory-reporting-in-healthcare>. Accessed September 11, 2019
122. Canadian Paediatric Society. Female genital mutilation/cutting. 2019. Available at: <https://www.kidsnewtocanada.ca/screening/fgm>. Accessed September 11, 2019
123. The Royal Australasian College of Physicians. *Female Genital Mutilation/Cutting*. Sydney, Australia: The Royal Australasian College of Physicians; 2012
124. The Royal Australian and New Zealand College of Obstetricians and Gynaecologists. Female genital mutilation (FGM). 2017. Available at: https://ranzcog.edu.au/RANZCOG_SITE/media/RANZCOG-MEDIA/Women%27s%20Health/Statement%20and%20guidelines/Clinical%20-%20

- 20Gynaecology/Female-Genital-Mutilation-(C-Gyn-1)-Nov17.pdf?ext=.pdf. Accessed April 30, 2020
125. Almroth L, Bedri H, El Musharaf S, et al. Urogenital complications among girls with genital mutilation: a hospital-based study in Khartoum. *Afr J Reprod Health*. 2005;9(2):118–124
 126. Diouf K, Nour N. Female genital cutting and HIV transmission: is there an association? *Am J Reprod Immunol*. 2013;69(suppl 1):45–50
 127. Armitage AJ, Bittaye M, Agbala S, Idoko P. Neonatal outcomes of female genital mutilation/cutting (fgm/c) in the Gambia: results from a multicentre prospective observational study. *Arch Dis Child*. 2018;103(suppl 1):A107

Diagnosis, Management, and Treatment of Female Genital Mutilation or Cutting in Girls

Janine Young, Nawal M. Nour, Robert C. Macauley, Sandeep K. Narang, Crista Johnson-Agbakwu, SECTION ON GLOBAL HEALTH, COMMITTEE ON MEDICAL LIABILITY AND RISK MANAGEMENT and COMMITTEE ON BIOETHICS

Pediatrics 2020;146;

DOI: 10.1542/peds.2020-1012 originally published online July 27, 2020;

Updated Information & Services

including high resolution figures, can be found at:
<http://pediatrics.aappublications.org/content/146/2/e20201012>

References

This article cites 68 articles, 14 of which you can access for free at:
<http://pediatrics.aappublications.org/content/146/2/e20201012#BIBL>

Subspecialty Collections

This article, along with others on similar topics, appears in the following collection(s):

Current Policy

http://www.aappublications.org/cgi/collection/current_policy

Committee on Bioethics

http://www.aappublications.org/cgi/collection/committee_on_bioethics

Committee on Medical Liability and Risk Management

http://www.aappublications.org/cgi/collection/committee_on_medical_liability_and_risk_management

Gynecology

http://www.aappublications.org/cgi/collection/gynecology_sub

International Child Health

http://www.aappublications.org/cgi/collection/international_child_health_sub

Permissions & Licensing

Information about reproducing this article in parts (figures, tables) or in its entirety can be found online at:

<http://www.aappublications.org/site/misc/Permissions.xhtml>

Reprints

Information about ordering reprints can be found online:

<http://www.aappublications.org/site/misc/reprints.xhtml>

American Academy of Pediatrics

DEDICATED TO THE HEALTH OF ALL CHILDREN®



PEDIATRICS®

OFFICIAL JOURNAL OF THE AMERICAN ACADEMY OF PEDIATRICS

Diagnosis, Management, and Treatment of Female Genital Mutilation or Cutting in Girls

Janine Young, Nawal M. Nour, Robert C. Macauley, Sandeep K. Narang, Crista
Johnson-Agbakwu, SECTION ON GLOBAL HEALTH, COMMITTEE ON
MEDICAL LIABILITY AND RISK MANAGEMENT and COMMITTEE ON
BIOETHICS

Pediatrics 2020;146;

DOI: 10.1542/peds.2020-1012 originally published online July 27, 2020;

The online version of this article, along with updated information and services, is
located on the World Wide Web at:

<http://pediatrics.aappublications.org/content/146/2/e20201012>

Pediatrics is the official journal of the American Academy of Pediatrics. A monthly publication, it has been published continuously since 1948. Pediatrics is owned, published, and trademarked by the American Academy of Pediatrics, 345 Park Avenue, Itasca, Illinois, 60143. Copyright © 2020 by the American Academy of Pediatrics. All rights reserved. Print ISSN: 1073-0397.

American Academy of Pediatrics

DEDICATED TO THE HEALTH OF ALL CHILDREN®

